

Symfysen hos fodboldspillere



Sonia Branci
Læge, Ph.d. stud.
Radiologisk Afdeling, Rigshospitalet

Symfyssen hos fodboldspillere

- Introduktion
- Fakta om langvarige lyskesmerter
- Anatomi
- Røntgenfund
- MR



Langvarige lyskesmerter

- Meget almindeligt problem hos fodboldspillere (og andre idrætsgrene)
- Rammer 10-15 % årligt
- Forbigående hos nogle
- Kroniske og svært invaliderende hos andre
- Mange mulige årsager

Langvarige lyskesmerter

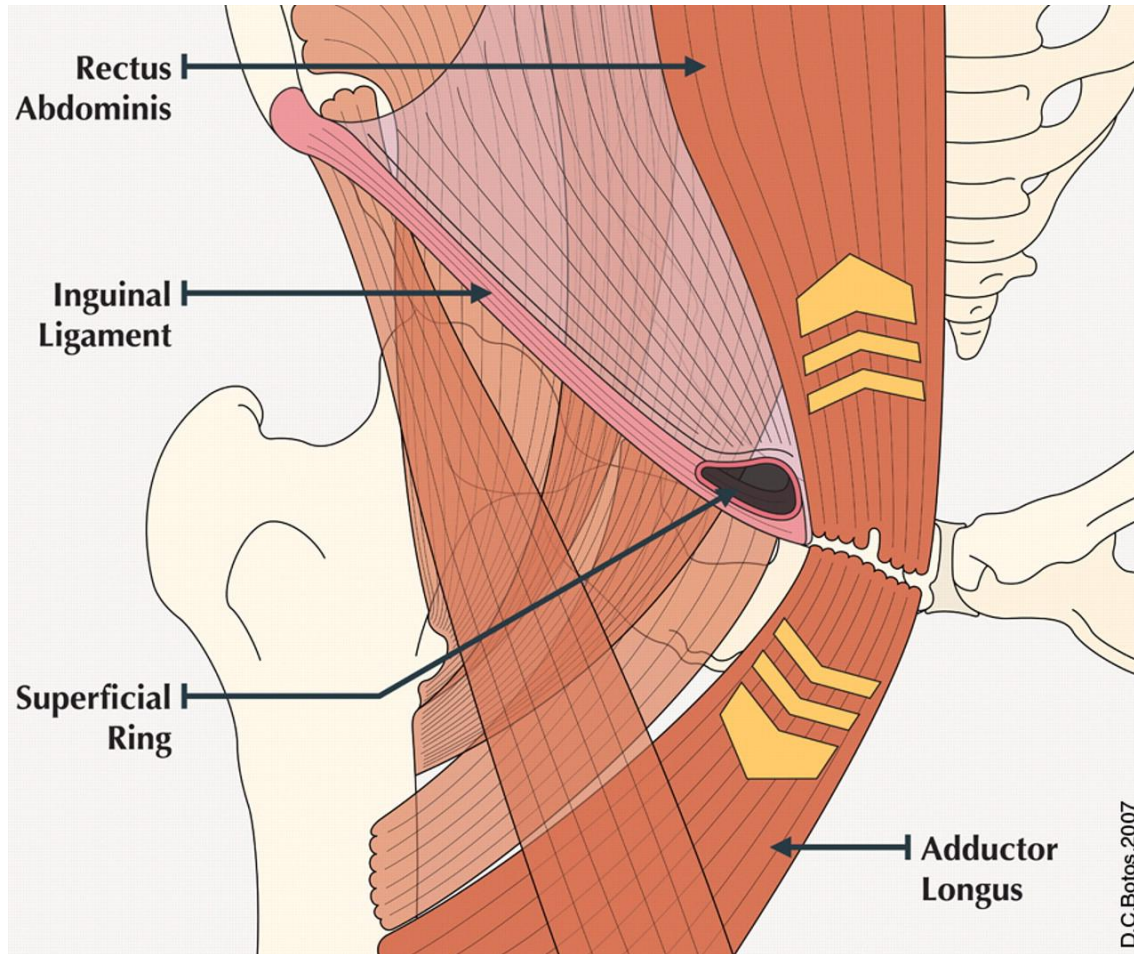
Orthopaedic Etiologies	Nonorthopaedic Etiologies
<u>Muscle</u>	<u>Hernia</u>
Adductor strain/tendonitis	Inguinal hernia
Rectus femoris strain/tear	Femoral hernia
Iliopsoas strain/tear	Preperitoneal lipoma
Rectus abdominis strain/tear	<u>Urologic</u>
Muscle contusion	Prostatitis
Gracilis syndrome	Epididymitis
Athletic hernia	Urethritis/UTI
<u>Bone/Joint</u>	Testicular neoplasm
Osteitis pubis	Ureteral colic
Degenerative joint disease: hip	Testicular torsion
Avascular necrosis: hip	Hydrocele/varicocele
Labral tear: hip	<u>Gynecologic</u>
Femoral neck fracture/stress fracture	Endometriosis
Pubic ramus stress fracture	Pelvic inflammatory disease
Myositis ossificans, adductors	Ovarian cyst
Slipped capital femoral epiphysis	<u>Surgical/GI</u>
Avulsion fracture: ASIS/AIS/Ischium	Rectal/colon neoplasm
<u>Nerve</u>	Inflammatory bowel disease
Lumbar radiculopathy	Diverticulitis
Ilioinguinal neuropathy	
Obturator neuropathy	
<u>Other Orthopaedic</u>	
Bone/soft tissue neoplasm of hip/pelvis	
Seronegative spondyloarthropathy	

Fokus

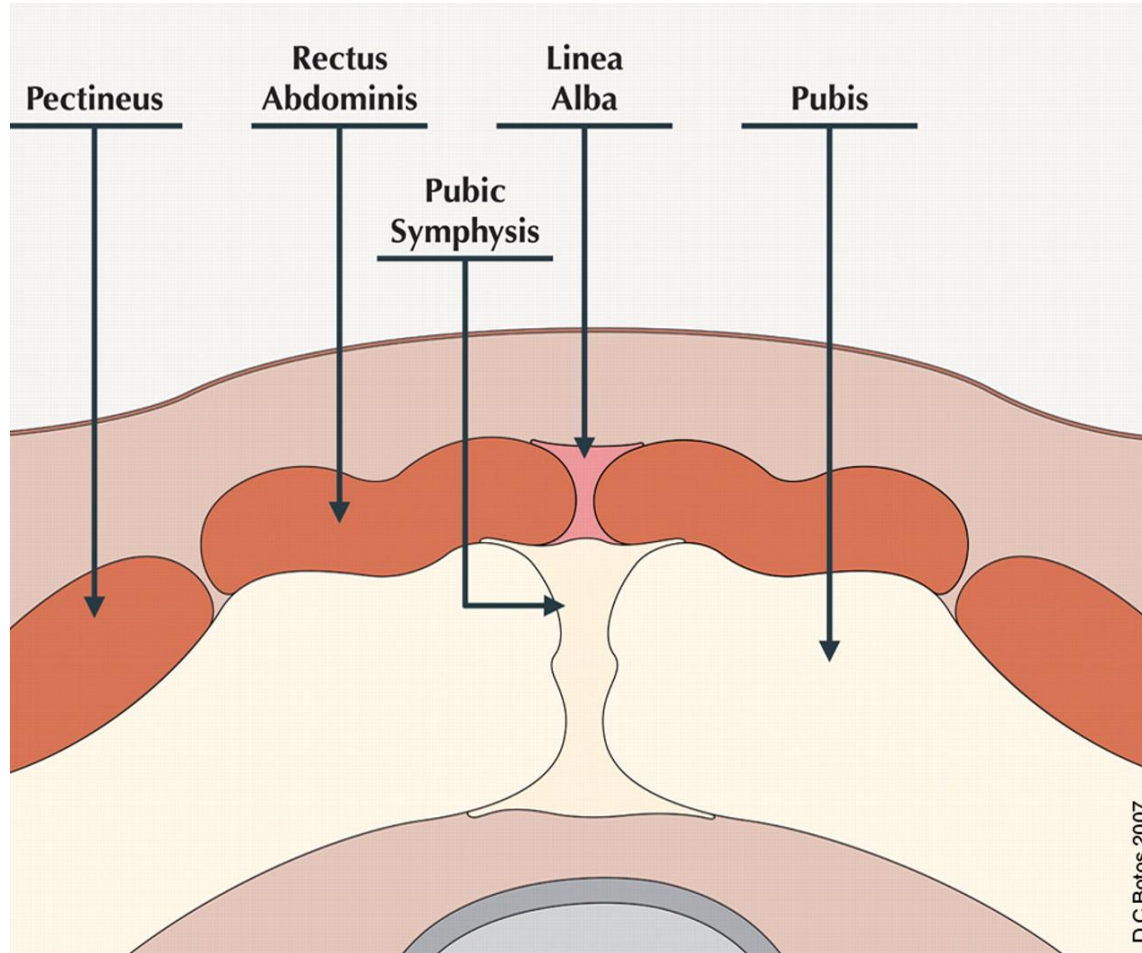
Symfyssen

M. adductor longus tilhæftningen til os pubis

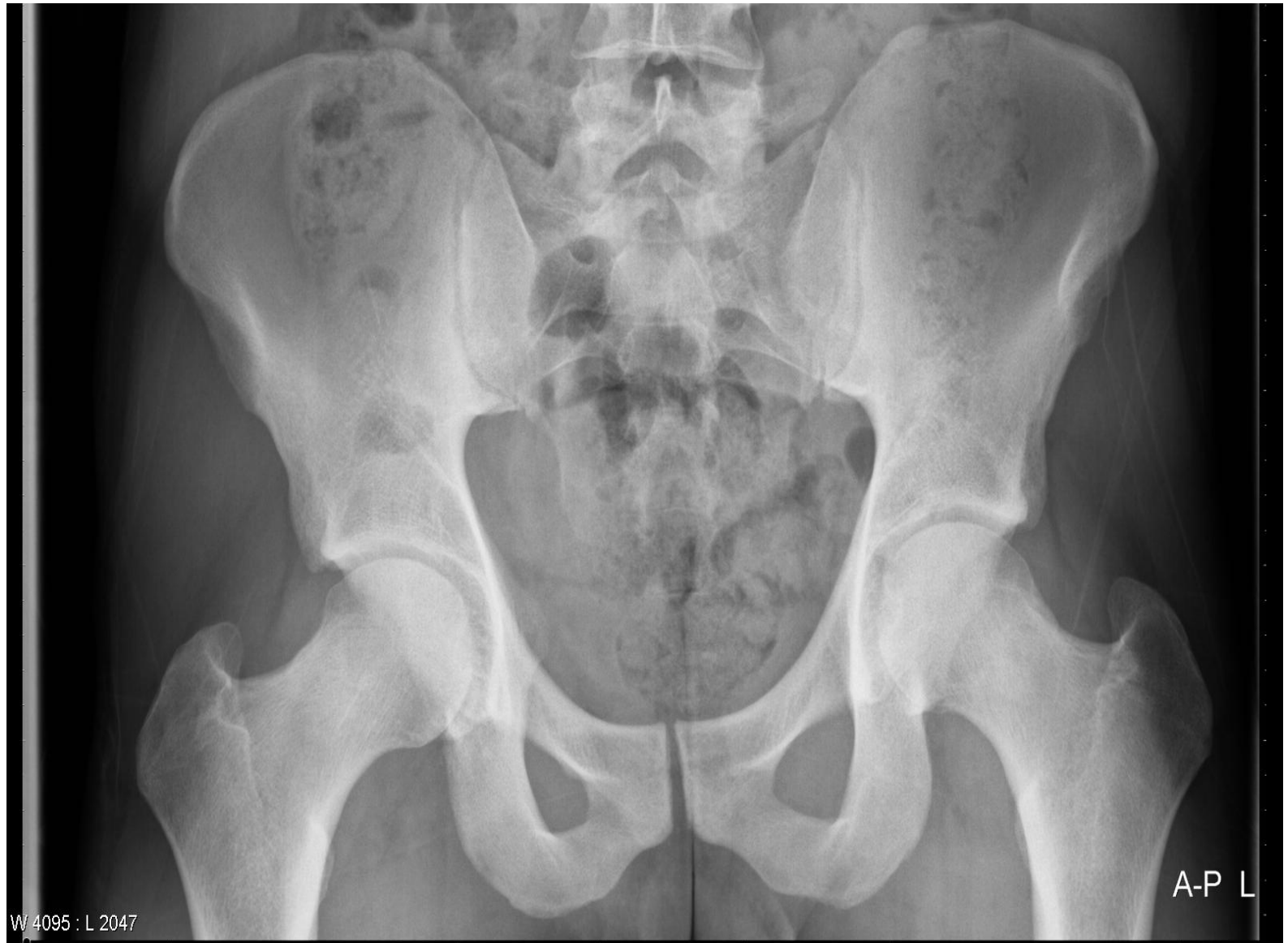Anatomi



Anatomi



Normalt røntgen

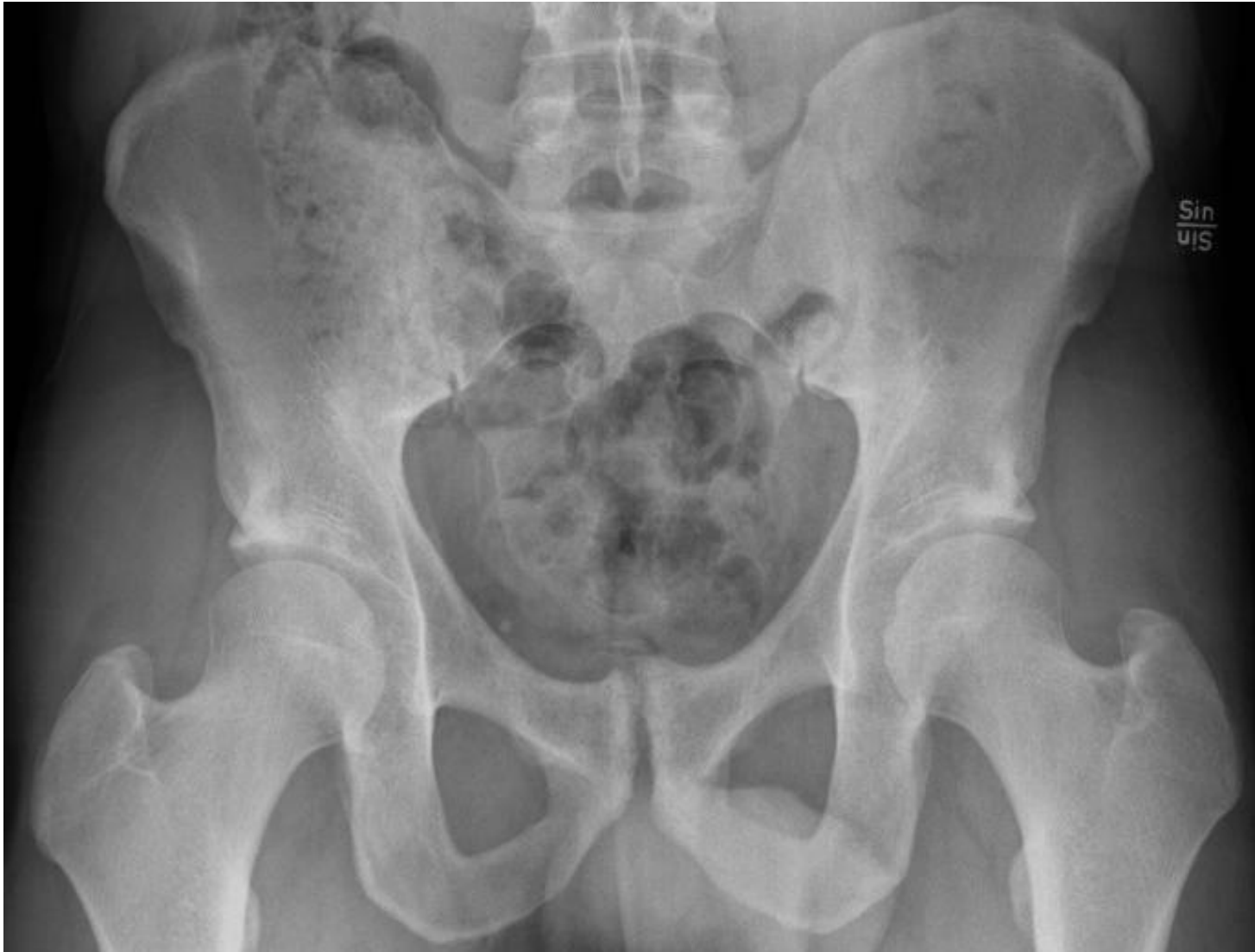

Røntgen forandringer hos fodboldspillere

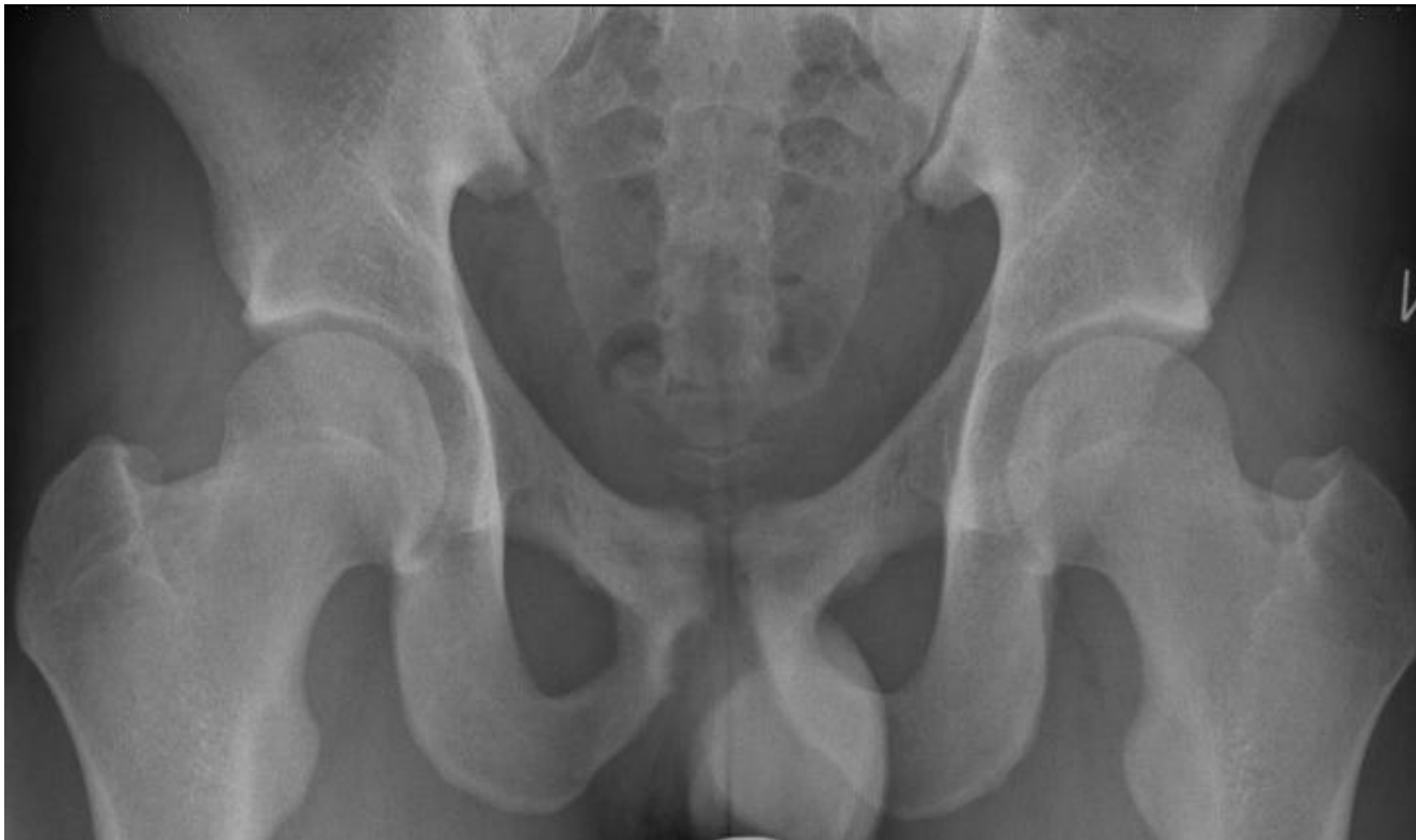Symfyseleddet:

- . Breddeøgning
- . Ujævn ledoverflade
- . Erosioner
- . Subkondrale cyster
- . Subkondral sklerosering
- . Asymmetri
- . Beaking

Degenerative forandringer



Degenerative forandringer



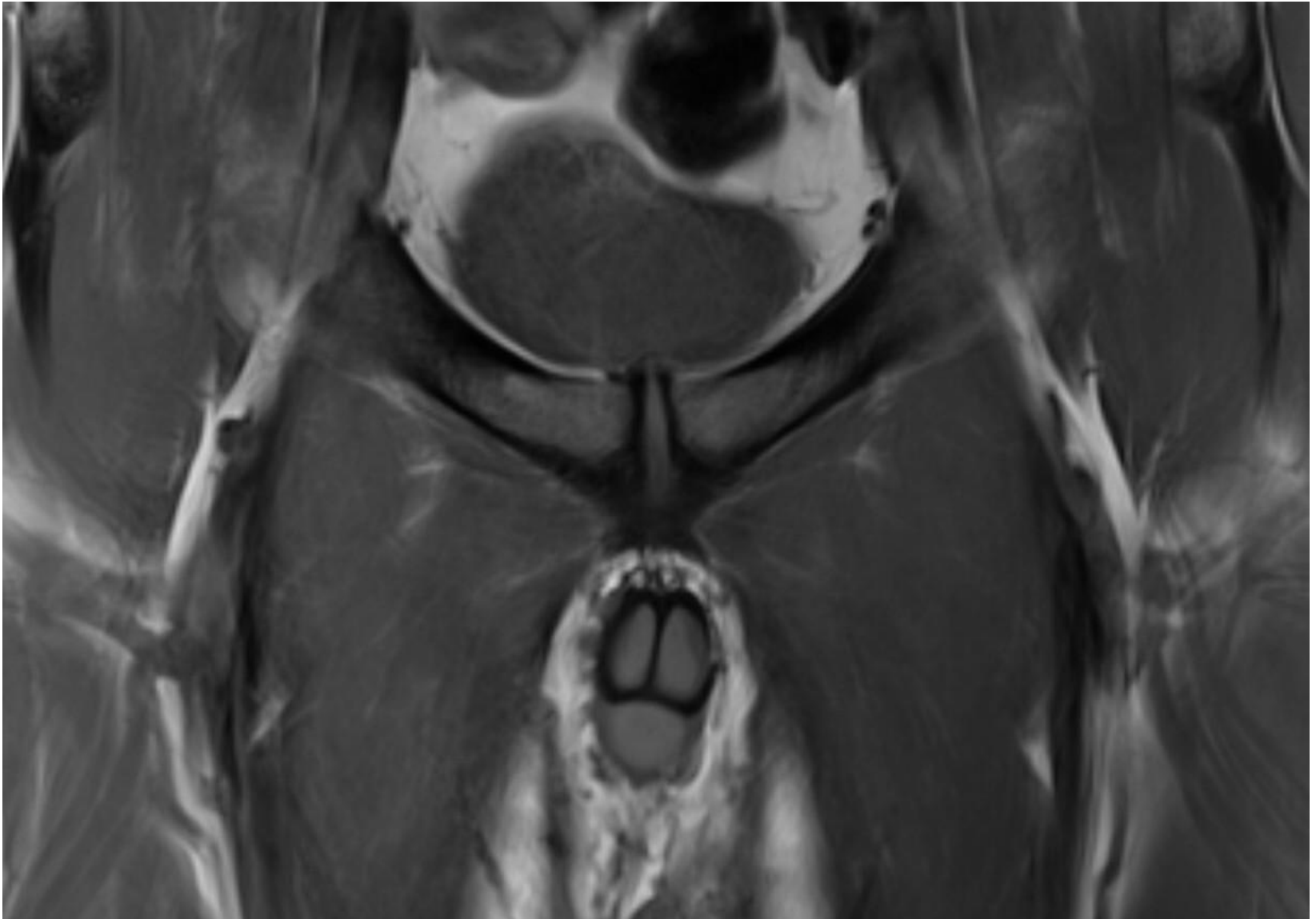
MR

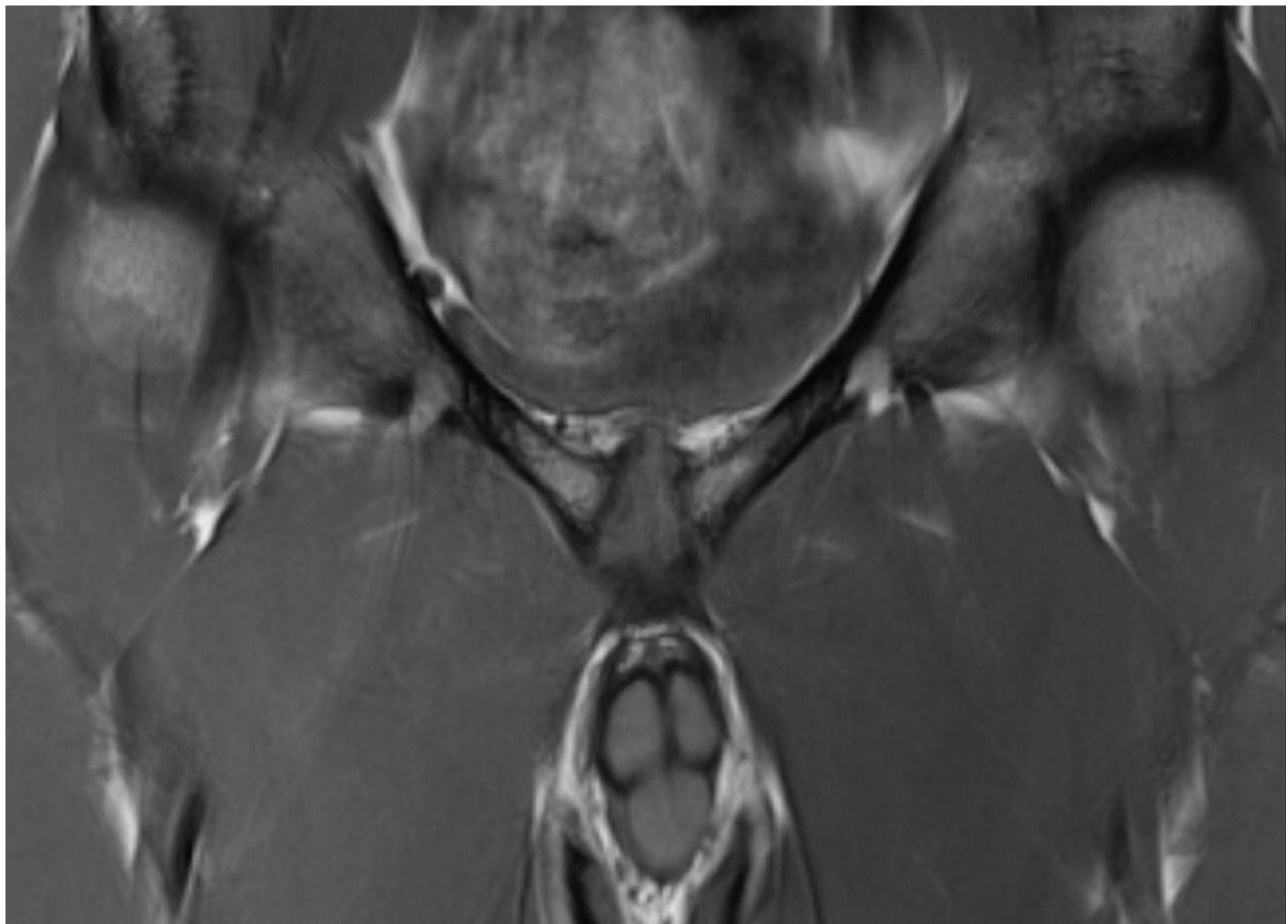
- T1 vægtede sekvenser : anatomi
- T2 vægtede, fedt-supprimerede sekvenser (STIR OG T2 FatSat) : ødem og væskesignal
- Ikke brug af kontrast
- Stort FOV og enkelte sekvenser med mindre FOV omkring symfyssen

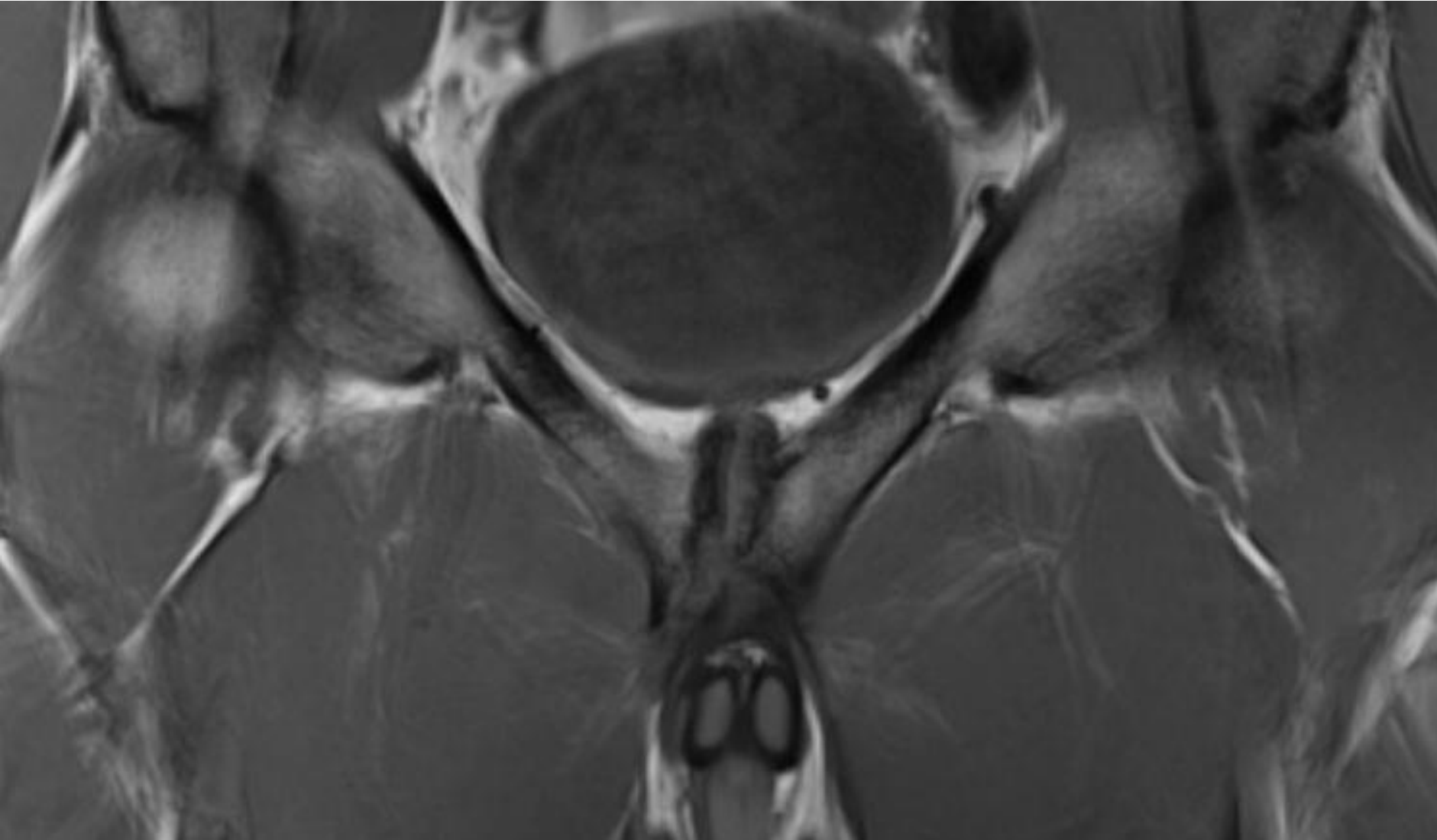
MR forandringer omkring symfyisen

- Degenerative
 - samme som røntgen
 - herniering af central discus i symfyseleddet
- Bone bruise (bone marrow edema)
- Ødem i/omkring adductor longus entesen
- Secondary cleft sign

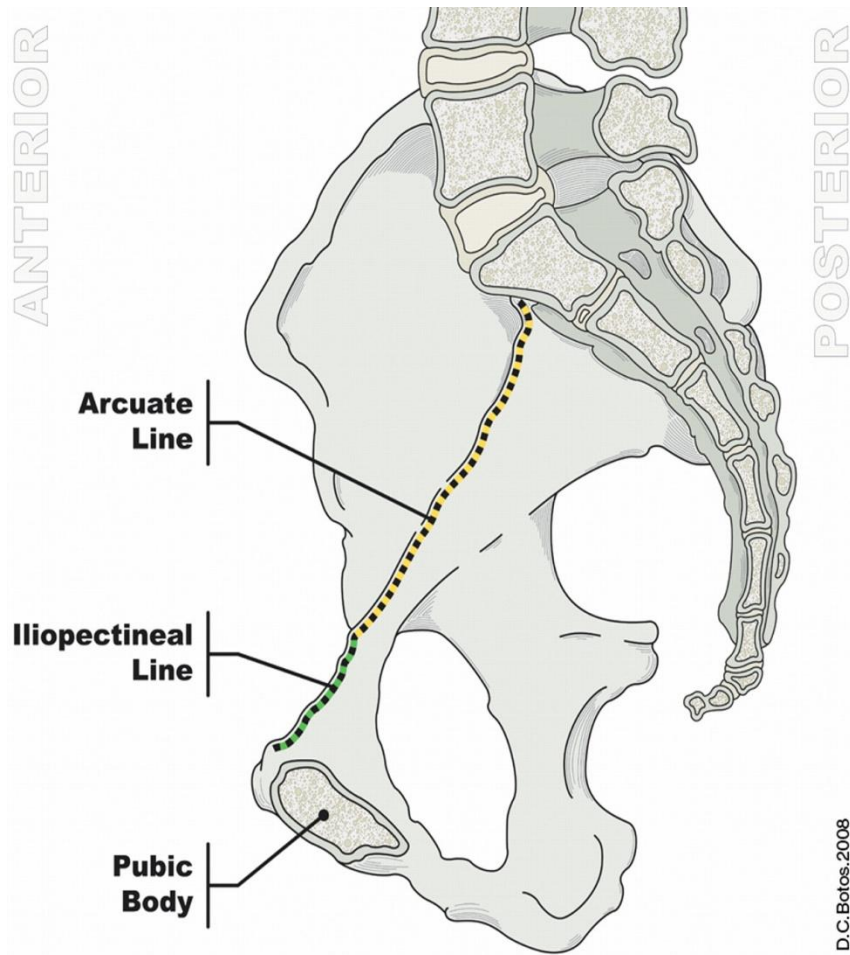
Symfysen



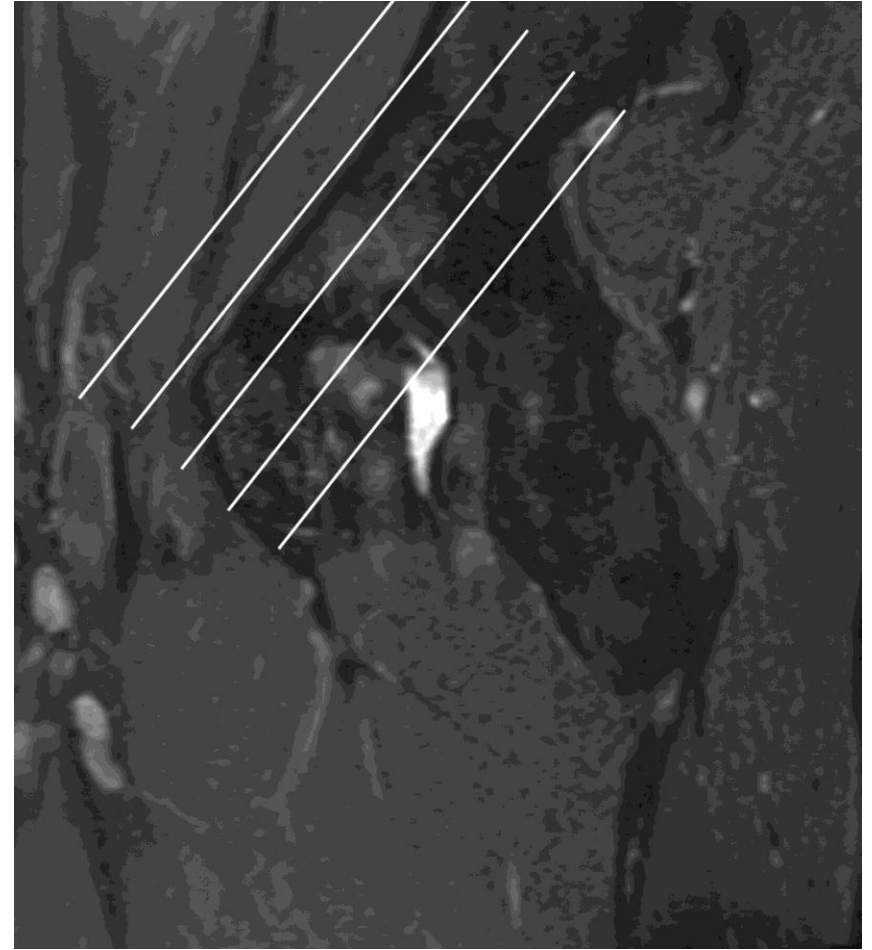




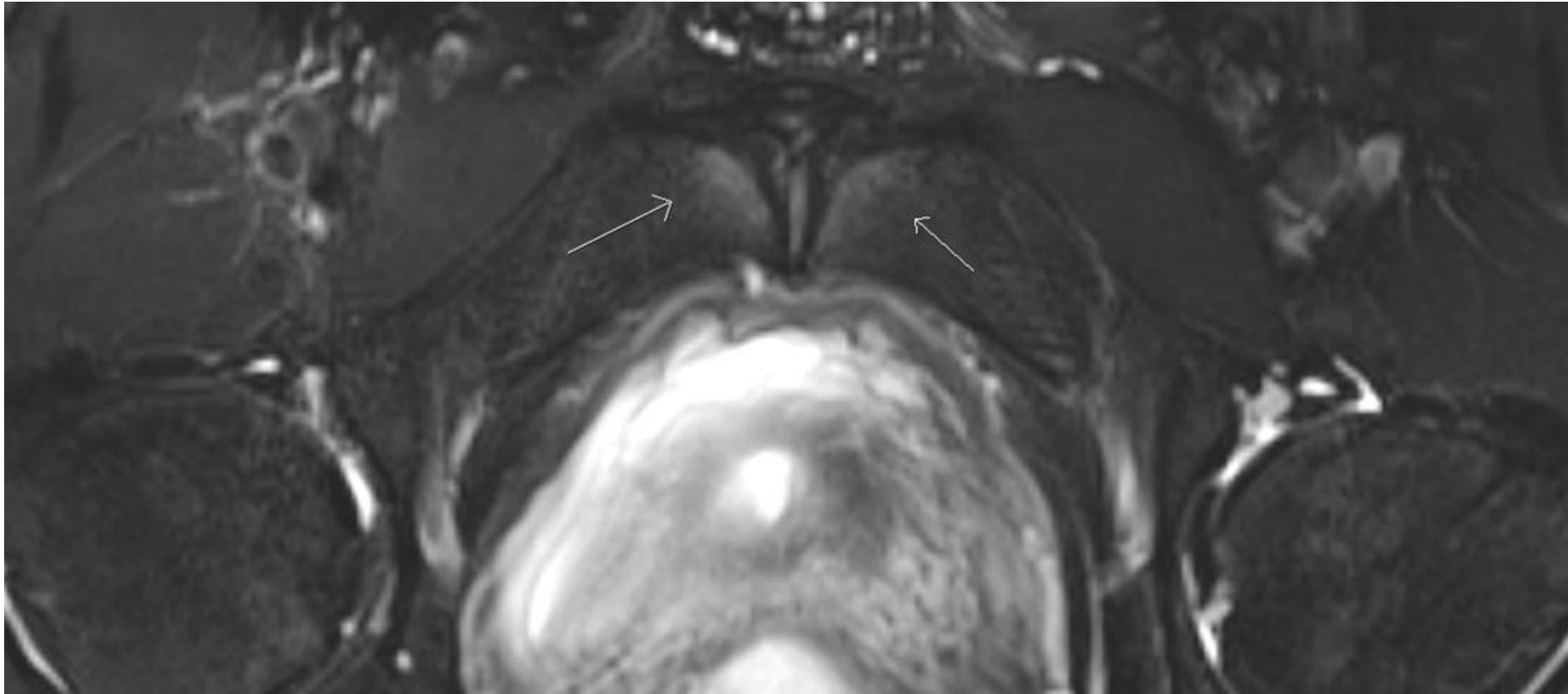
Para-axial optagelse Adductor logen



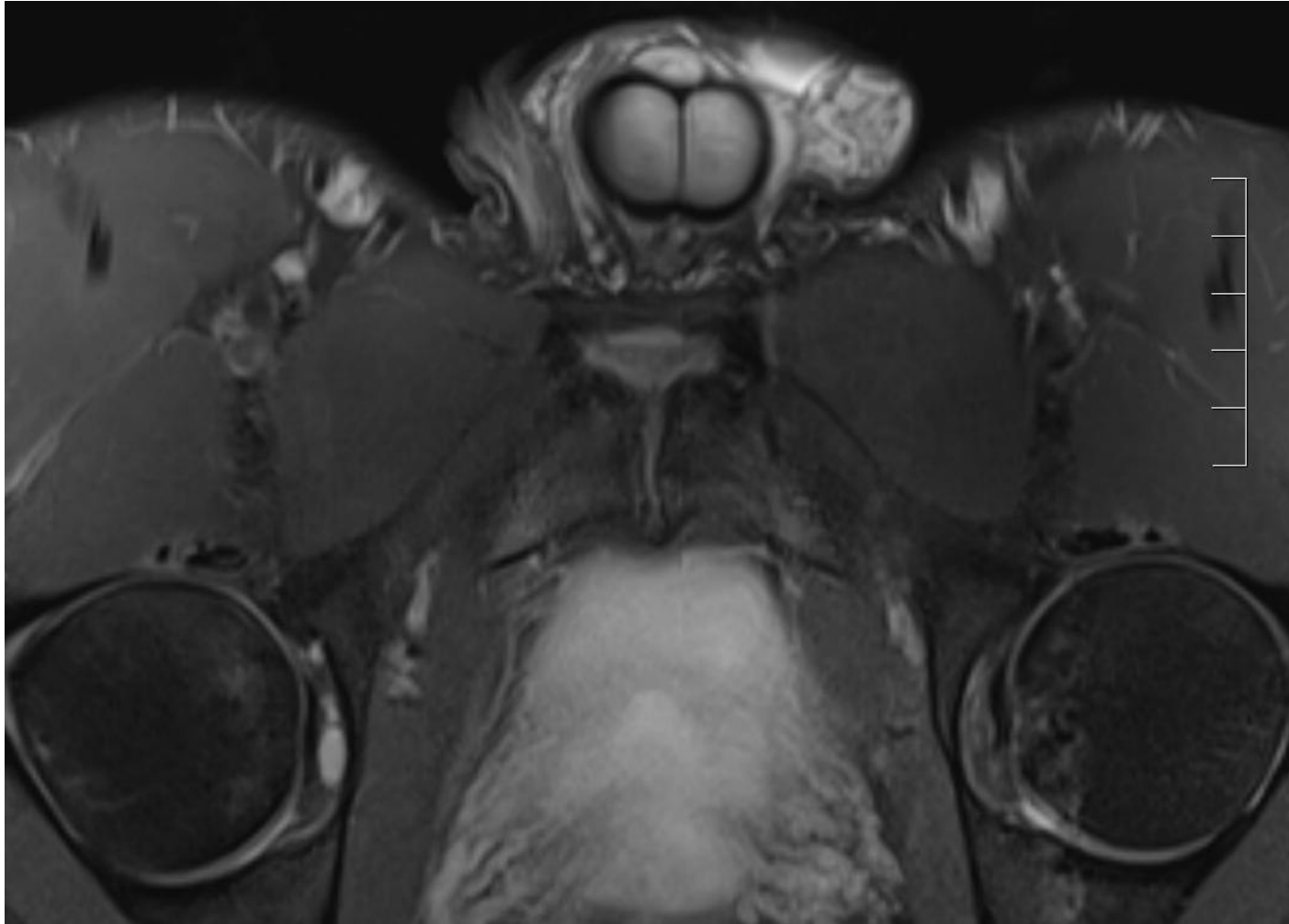
D.C. Botos.2008



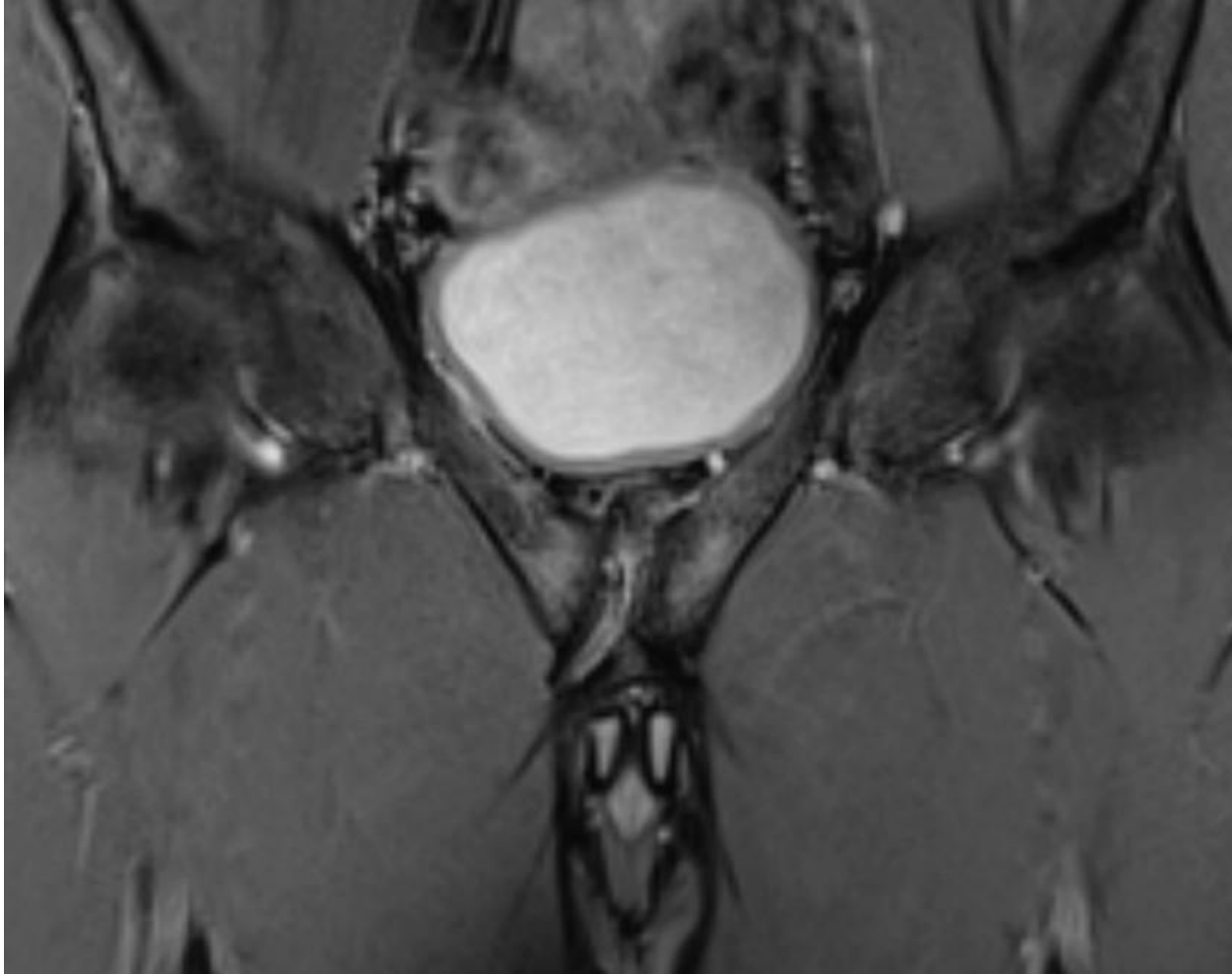
Bone bruise

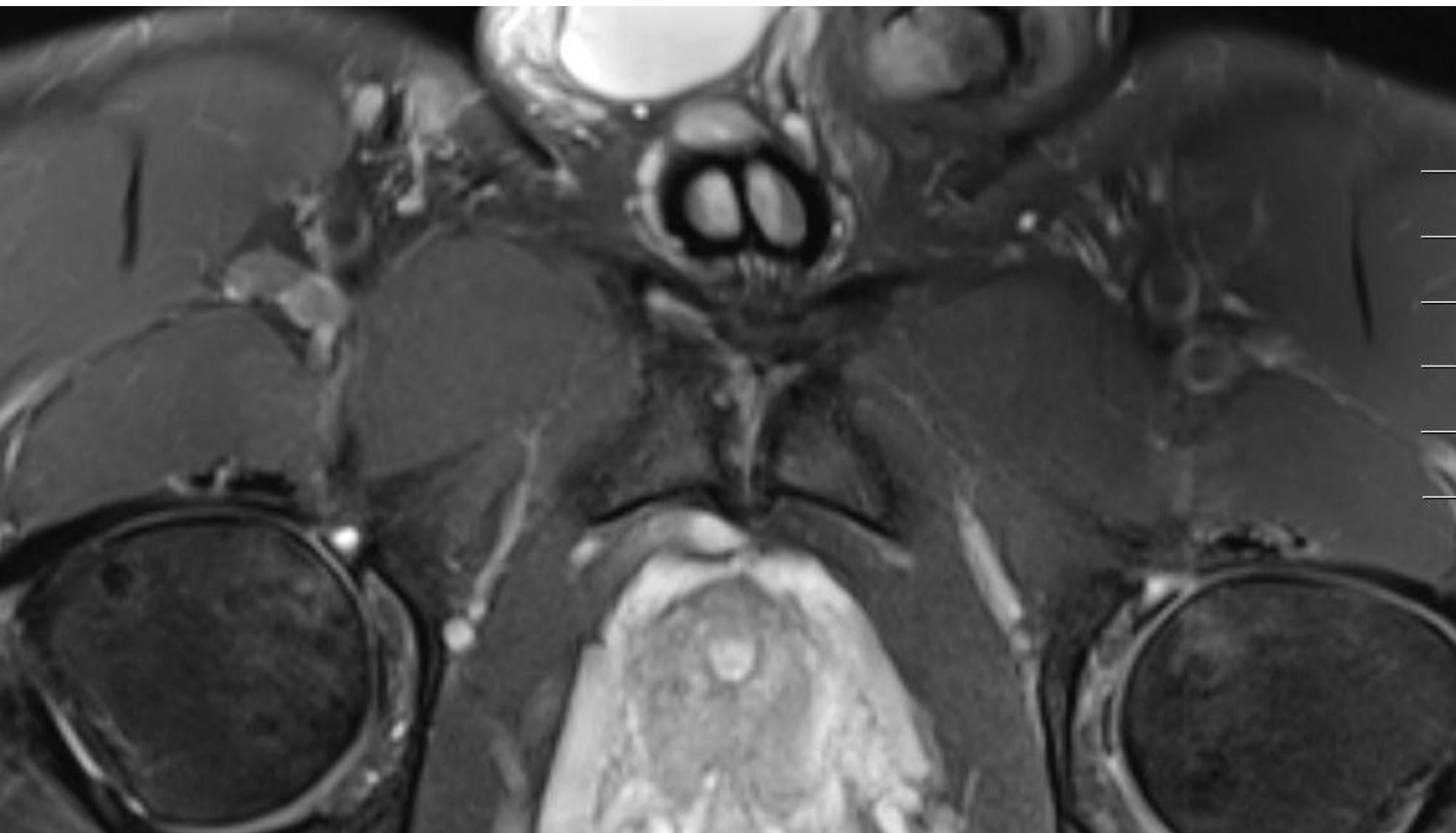


Adductor longus entesen

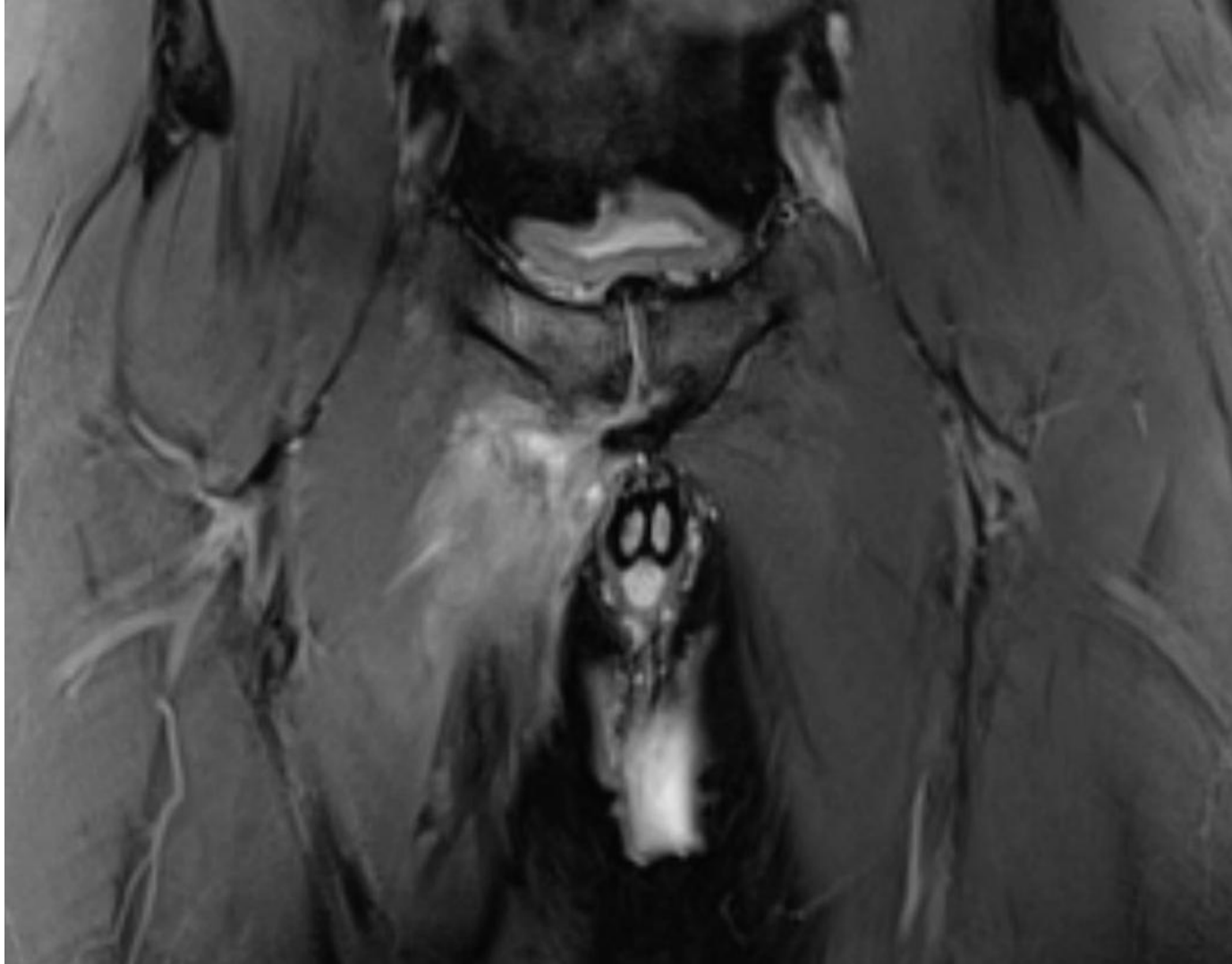

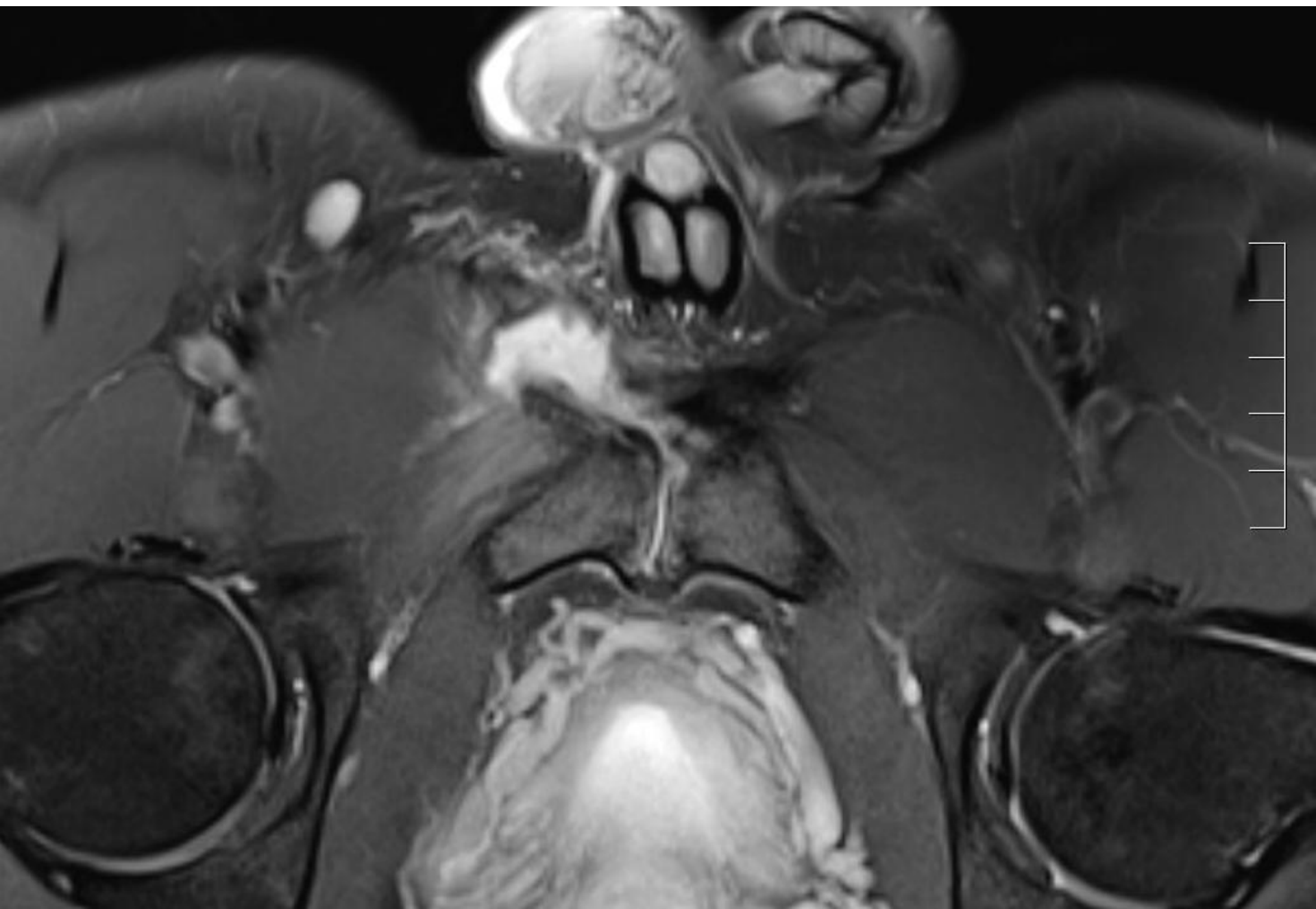
Secondary cleft sign





Akut adductor longus læsion





Konklusion

- Akutte skader vs. langvarig overbelastning
- Idrætsrelateret fysiologisk stress
- Mangel på:
 - tydelige radiologiske definitioner
 - studier som belyser sammenhængen ml. klinik og radiologi