^{18}F-FDG-PET/CT ved malignt lymfomt

Karin Hjorthaug,
Nuklearmedicinsk afd & PET center
AArhus Universitets Hospital

DRS årsmøde jan 2012

18F-Fluoro-Deoxy-Glukose (18F-FDG)

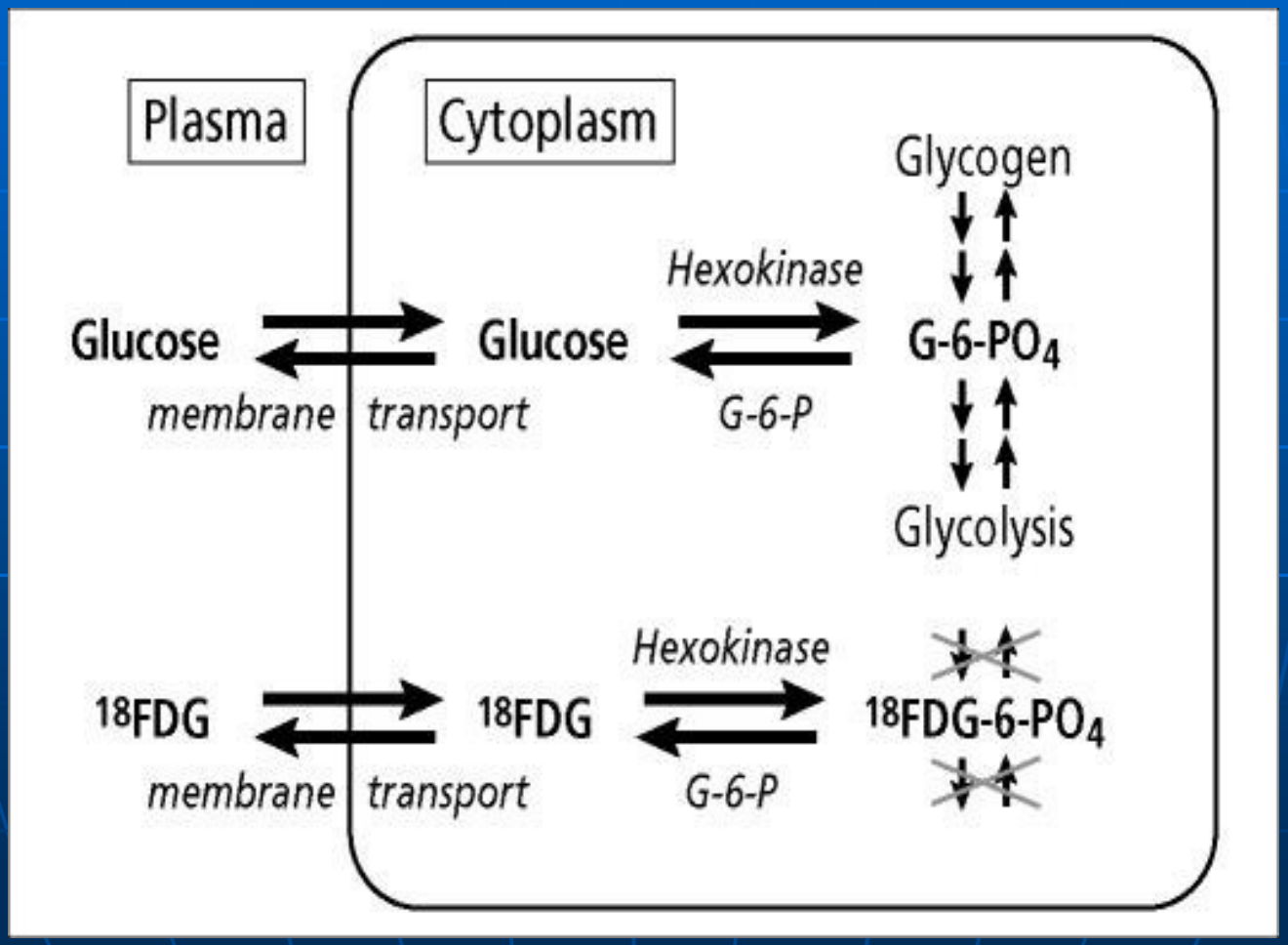

^{18}F-FDG

- Glukoseoptagende celler
- Øget optagelse i
  - Maligne celler
  - Inflammatoriske celler (neutrofile leukocytter, makrofager, lymfocytter)

INGEN CANCER-SPECIFIK SKANNING!!

Er lymfomer FDG optagende?

Table 22.4 FDG PET imaging in subtypes (REAL/WHO classification) of lymphomas

Subtype	Clinical course	FDG uptake patterns
HD		
Classical HD (most common)	Aggressive	High FDG uptake ≥95% positive
Lymphocyte-predominance HD	Aggressive	FDG uptake may be < classical HD
NHL		
DLCL (most common)	Aggressive	High FDG uptake ≥95% positive
Follicular (second most common)	Low-grade	Moderate to low FDG uptake ≤90% positive
Transformed follicular	Aggressive	High FDG uptake ≥95% positive
Small lymphocytic lymphoma/chronic *Lymphocytic leukemia* (*CLL/SLL*)	Low-grade	Low to undetectable FDG uptake 60–70% positive
Extranodal Marginal zone/MALT	Low-grade	Varies from low-to-undetectable to high ≤70% positive
Nodal Marginal Zone	Low-grade	High FDG uptake ≥95%
Burkitt's	Aggressive	High FDG uptake ≥95% positive
T/natural killer cell	Aggressive	High FDG uptake ≥95% positive
Peripheral T-cell	Aggressive	Low-to-undetectable FDG uptake ≤50%
Mantle cell	Aggressive	High-to-moderate FDG uptake ≥90% positive
CNS lymphoma	Aggressive	High FDG uptake (> adjacent gray matter) ≥95% positive

Bone marrow involvement may not be reliably assessed by PET imaging; however, FDG PET is highly reliable in primary or bone involvement of advanced stage disease.

Er lymfomer FDG optagende?

Table 22.4 FDG PET imaging in subtypes (REAL/WHO classification) of lymphomas

Subtype	Clinical course	FDG uptake patterns
HD		
Classical HD (most common)	Aggressive	High FDG uptake ≥95% positive
Lymphocyte-predominance HD	Aggressive	FDG uptake may be < classical HD
NHL		
DLCL (most common)	Aggressive	High FDG uptake ≥95% positive
Follicular (second most common)	Low-grade	Moderate to low FDG uptake ≤90% positive
Transformed follicular	Aggressive	High FDG uptake ≥95% positive
Small lymphocytic lymphoma/chronic	Low-grade	Low to undetectable FDG uptake 60–70% positive
Lymphocytic leukemia (CLL/SLL)		
Extranodal Marginal zone/MALT	Low-grade	Varies from low-to-undetectable to high ≤70% positive
Nodal Marginal Zone	Low-grade	High FDG uptake ≥95%
Burkitt's	Aggressive	High FDG uptake ≥95% positive
T/natural killer cell	Aggressive	High FDG uptake ≥95% positive
Peripheral T-cell	Aggressive	Low-to-undetectable FDG uptake ≤50%
Mantle cell	Aggressive	High-to-moderate FDG uptake ≥90% positive
CNS lymphoma	Aggressive	High FDG uptake (> adjacent gray matter) ≥95% positive

Bone marrow involvement may not be reliably assessed by PET imaging; however, FDG PET is highly reliable in primary or bone involvement of advanced stage disease.

Glukosemetabolisme og histologi - *"tommelfingerregel"?*

- Højmaligne
  - Næsten altid FDG optagende - og ofte kraftigt
- Lavmaligne
  - Varierende FDG optagende - og ofte svagt

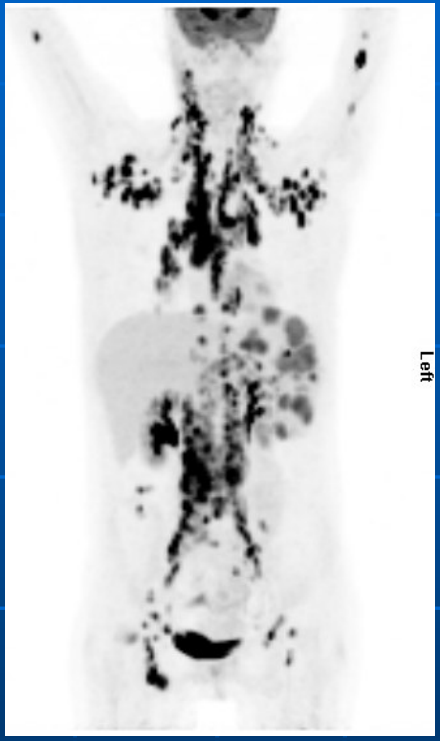

Diffust storcellet B-lymfom

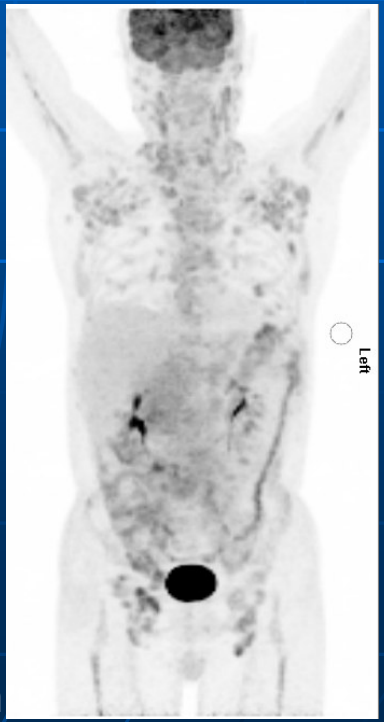

Follikulært lymfom

Hvilke lymfomer PET skannes?

Generelt de potentielt kurable!

~ overvejende de aggressive

Men også nogle lavmaligne

~ follikulært lymfom

Hvad er PET (generelt) god til?

Patient med lymfom

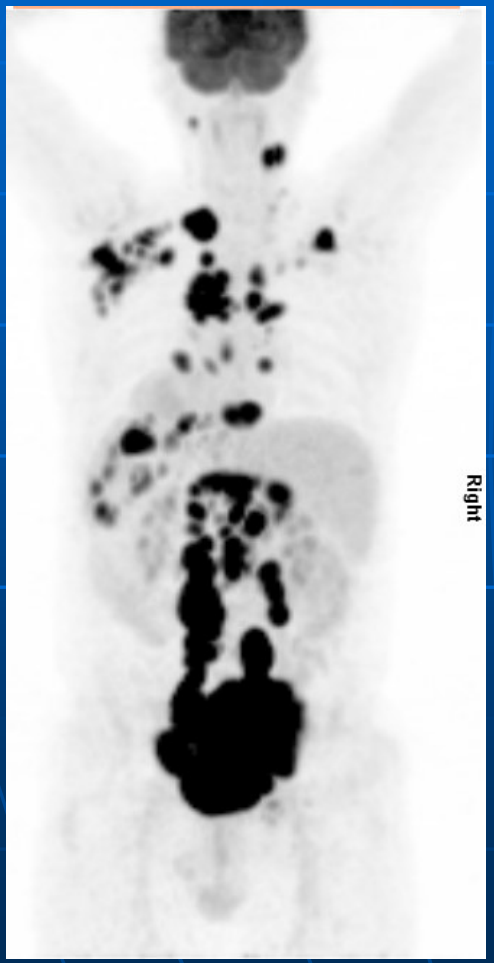

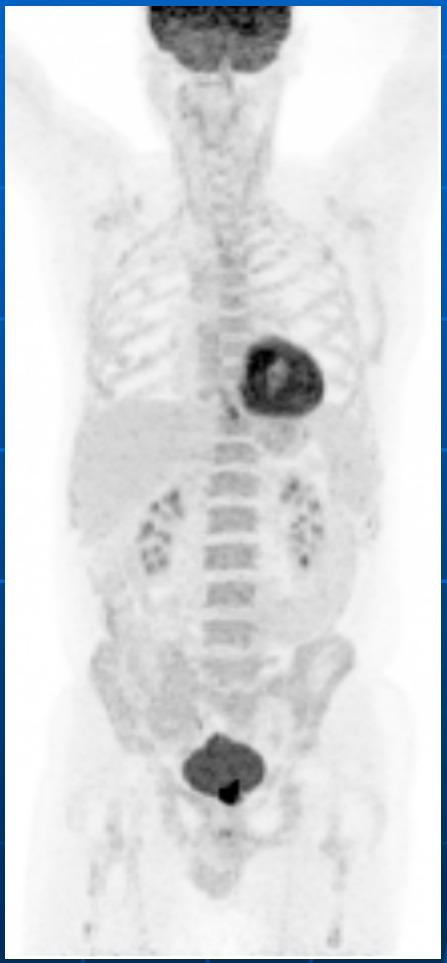

Høj signal/baggrund kontrast

PET er en helkropsskanning – ”screening”.

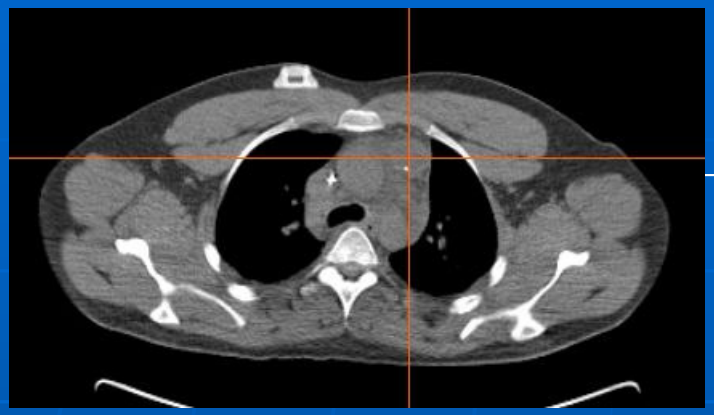

Patient med lymfom

Postterapeutisk evaluering



CT: restvæv

PET: negativ

PET vurderer sygdomsaktiviteten i restvæv

Follikulært lymfom. Postterapeutisk PET/CT.

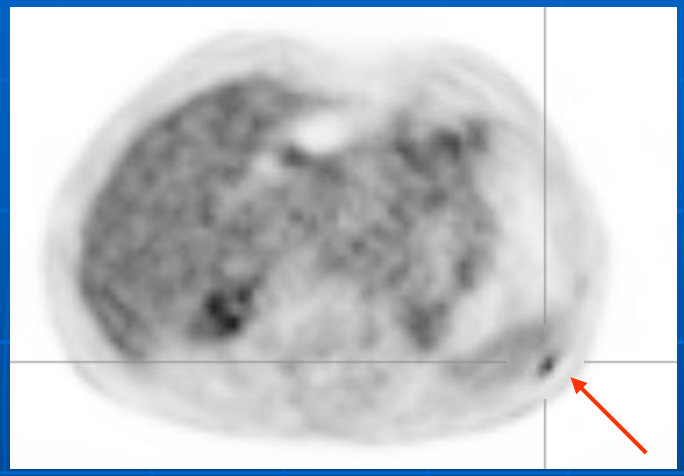

CT: ingen patologiske LK

PET: PET positive LK

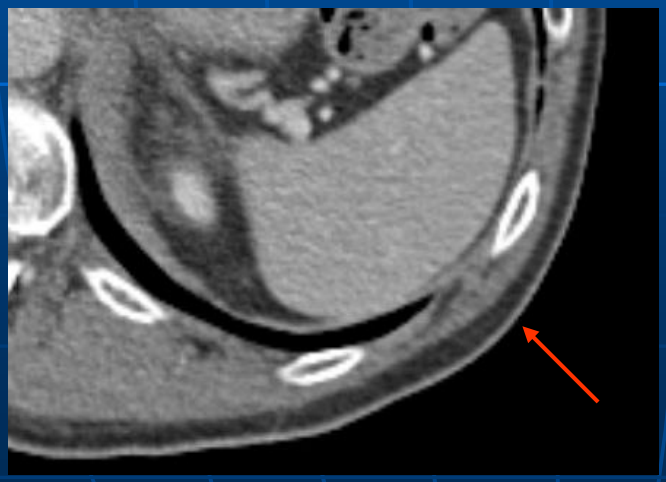

PET kan detektere syge lymfeknuder som ikke er patologisk forstørrede

PET og knoglemarv

Reaktiv KM hyperplasi

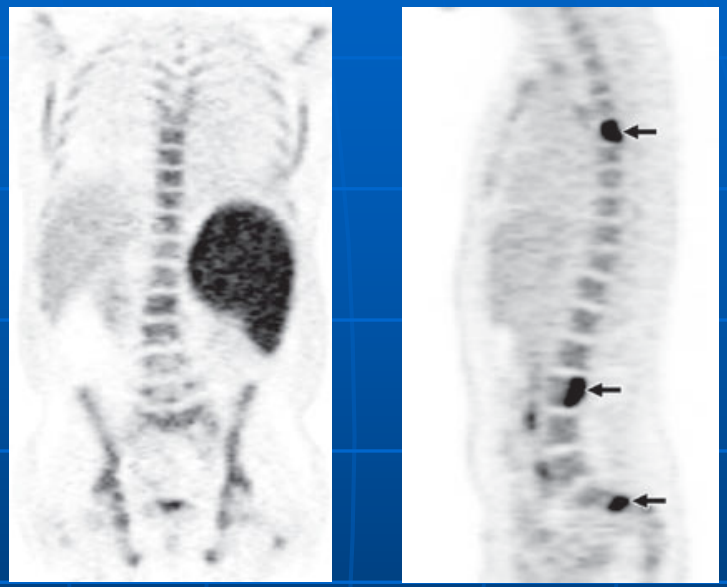

KM involvering

Selvom KM biopsi er negativ er *fokale* PET positive fund i KM suspekte for KM involvering

Cronin CG et al AJR: 194 Jan 2010

PET og knoglemarv

- 614 pt
  - KM pos - PET neg: 50
  - KM pos - PET pos: 43
  - KM neg - PET pos: 56

PET pos knogle/knoglemarvs fund bør verificeres med biopsi eller MR

Cheson, J Clin Oncol 2011

PET og knogle-/knoglemarv

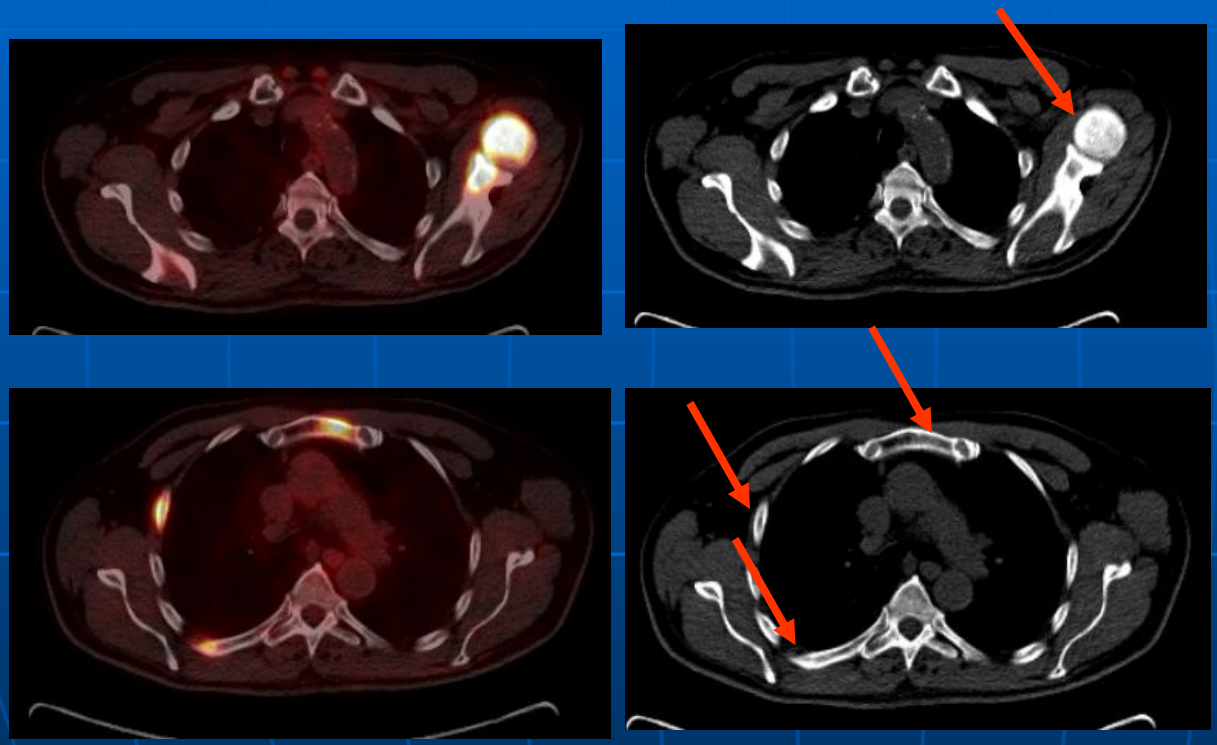

CT viser helt normal knoglestruktur

CT kan ikke anvendes til vurdering af knogle-/knoglemarvsinvolvering

Hvad er PET ikke god til?

Kvinde med CCU. Metastaser?

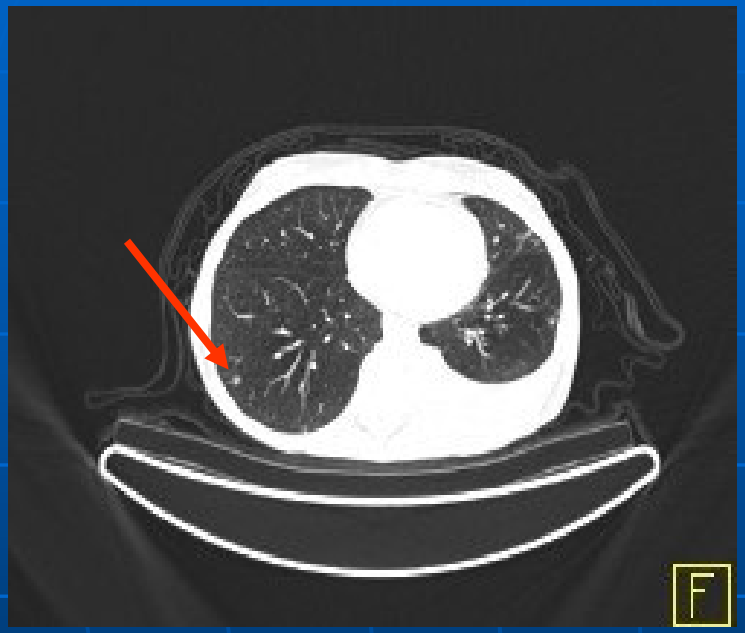

PET kan ikke detektere (undervurderer) små foci < 6-7 mm

PET vanskelig i områder med høj fysiologisk aktivitet

Feks ved…..

- CNS lymfom
- Gastrisk lymfom
- Testikulær lymfom
- ……

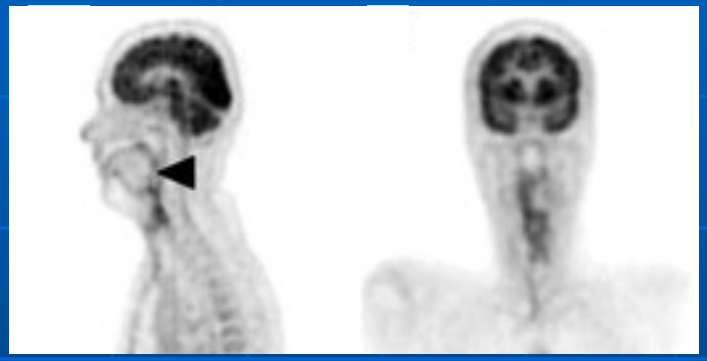

Bruges dog til at udelukke/vurdere lymfominvolvering andet sted

”Falsk positiv PET”

- Granulomatøs sygdom
- Infektion
- Thymus hyperplasi
- Brunt fedt
- Trombose
- Strålesequelae

Antallet af ”falsk positive” fund nedsættes betragteligt ved fusion med CT (lavdosis CT)

Brunt fedtvæv

Inflammation/infektion

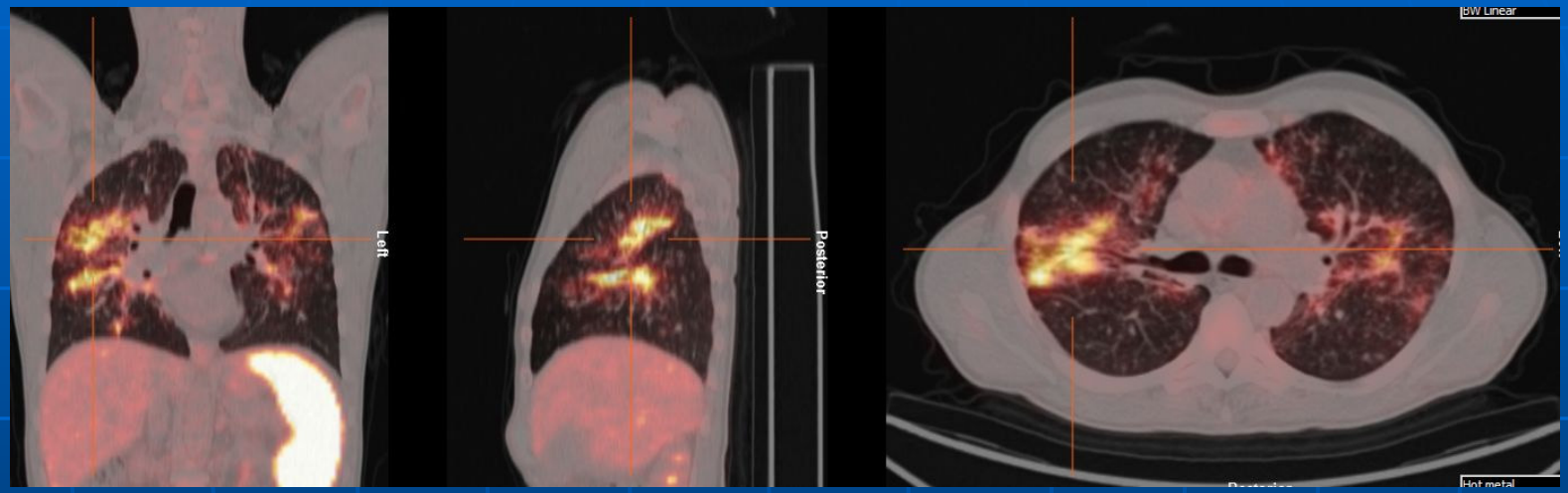

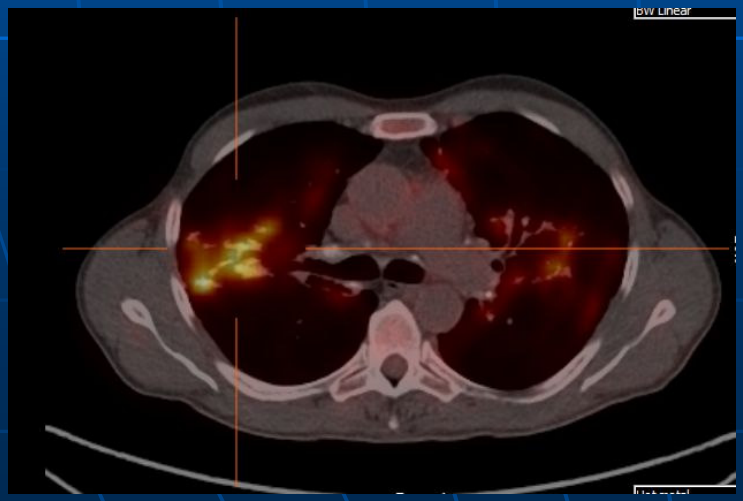

Burkitt Lymfom

Postterapeutisk skanning

Lymfom? Sarkoidose?

FDG optagelse i thymus

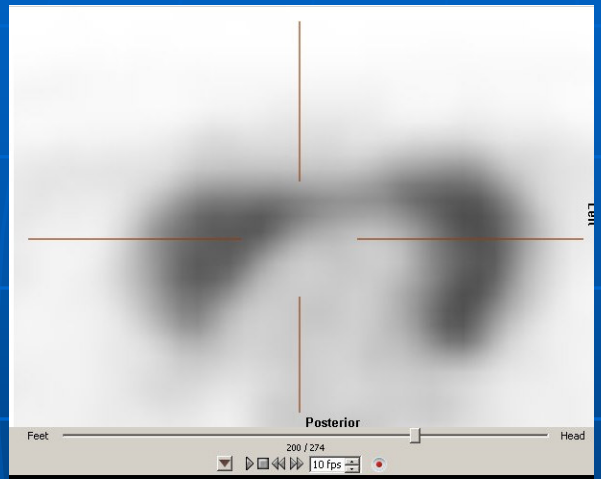

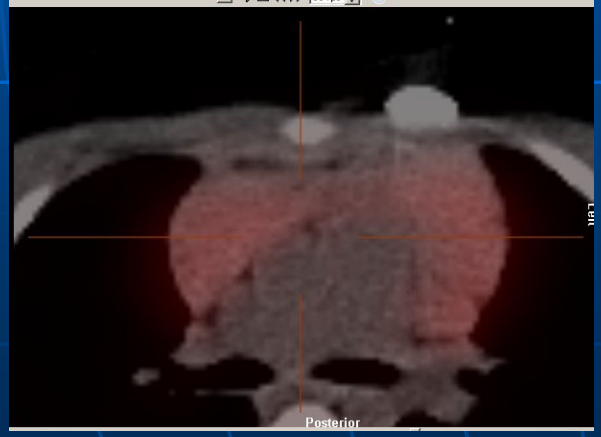

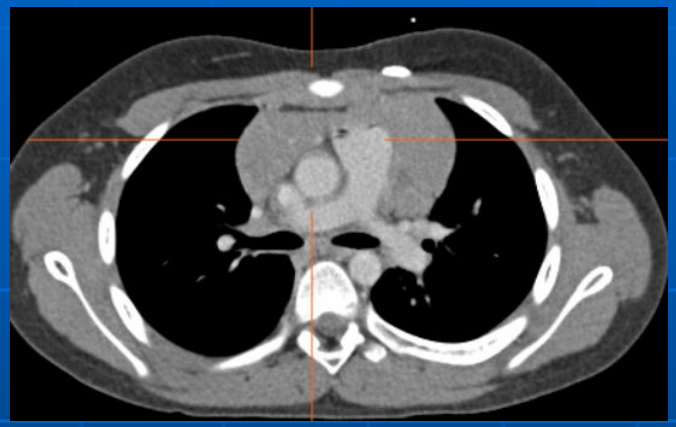

Specifikke indikationer

- Staging præterapeutisk
- Behandlingsmonitorering (interim PET)
- Postterapeutisk skanning
- Malign transformation (biopsi guide)
- Mistanke om recidiv
- Før stam-celle transplantation

- Ingen indikation for follow-up!!

Staging

- PET betyder up-staging for 15-20%
  - Flere lymfeknuder og organinvolvering
- PET ændrer management hos 10-15%

Seam P. et al. Blood 2007
Rigacci L et al. Ann Hematol 2007

Postterapeutisk skanning

- PET er bedre end CT til at adskille aktivt tumorvæv fra fibrose i restvæv
- God til at udelukke sygdom!
- Den PPV generelt lidt lavere – og mere varierende

Interim PET - Hodgkin

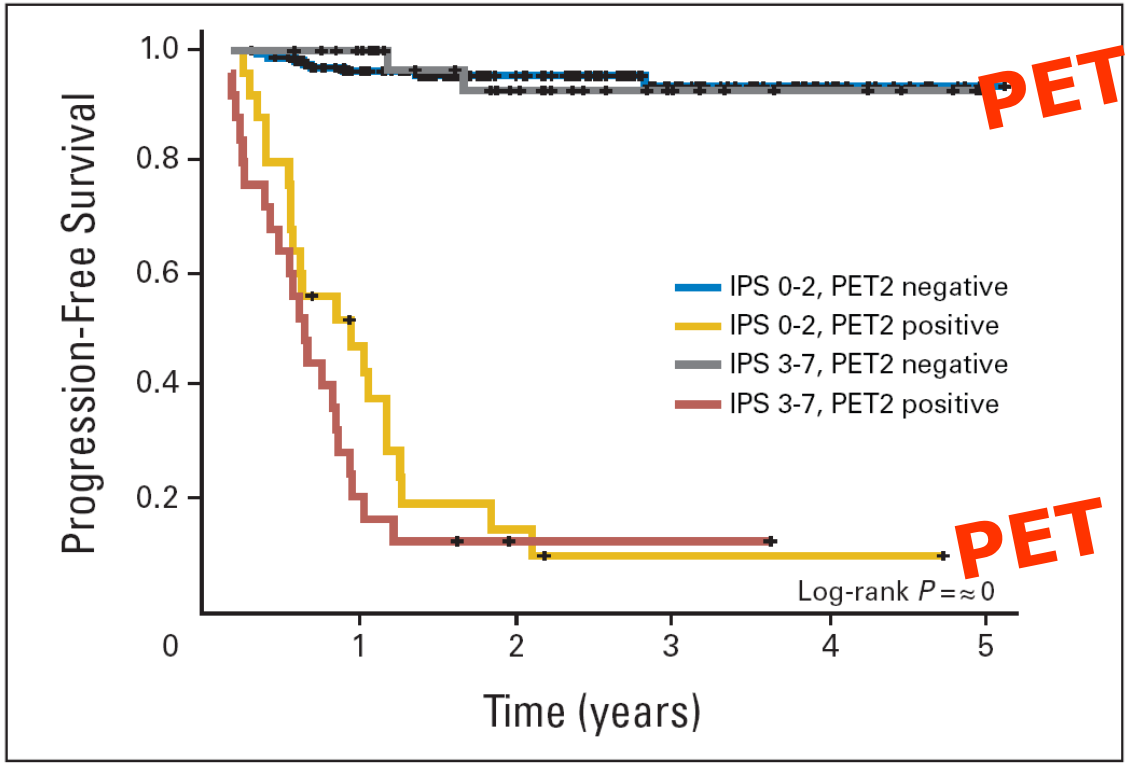

Fig 3. Kaplan-Meier plot showing the progression-free survival according to International Prognostic Score (IPS) group and positron emission tomography results after two cycles of ABVD (doxorubicin, bleomycin, vinblastine, and dacarbazine).

Interim skanning

Mb Hodgkin

- Interim PET vigtigste prognostiske faktor
- Surrogatmål for kemosensitivitet
- Opdeler patienter i responders og non-responders

Endnu ikke vist hvad PET guided ændring i behandling betyder for overlevelsen

Behandlingsrespons

- Konklusion
  - Størrelsesmæssige og metaboliske forhold
  - Komplet eller partiel regression, stabil sygdom, progression eller blandet respons
  - CT baseret på ”Cheson kriterier”
  - PET baseret på ”Deauville score”

Hvornår er PET positiv?

Deauville kriterier:

en 5-punktsskala med mediastinum og lever som reference

FDG-optagelse

1. Ingen optagelse, ingen læsioner
2. Optagelse < mediastinum
3. Optagelse > mediastinum men ≤ lever
4. Optagelse ≥ lever
5. Optagelse >> lever, nye læsioner

Hvornår er PET positiv?

- Kriterierne standardiserer

- Cut-off point for ”positivitet”
  - tidpunkt for skanning
  - om man ønsker at øge eller nedsætte beh
  - histologi
  - Kemoterapeutika (rituximab)

DLBCL

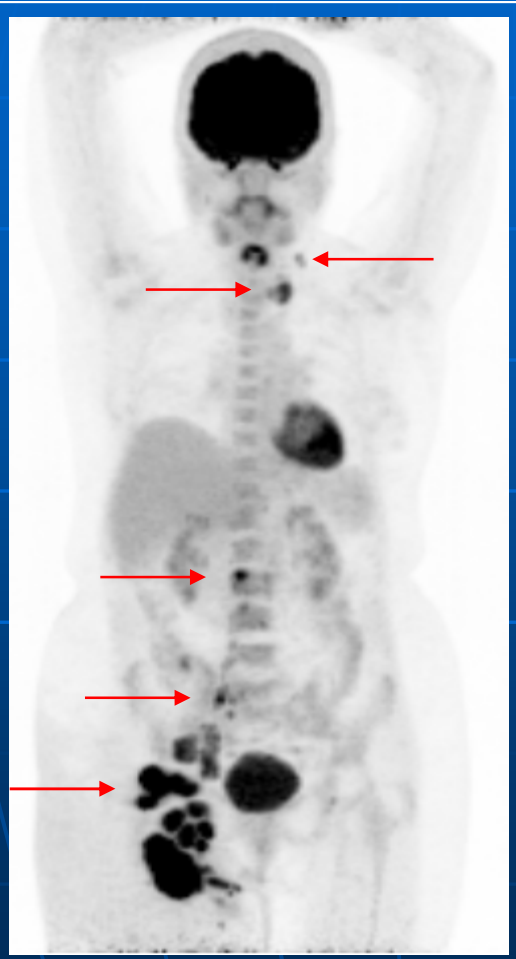

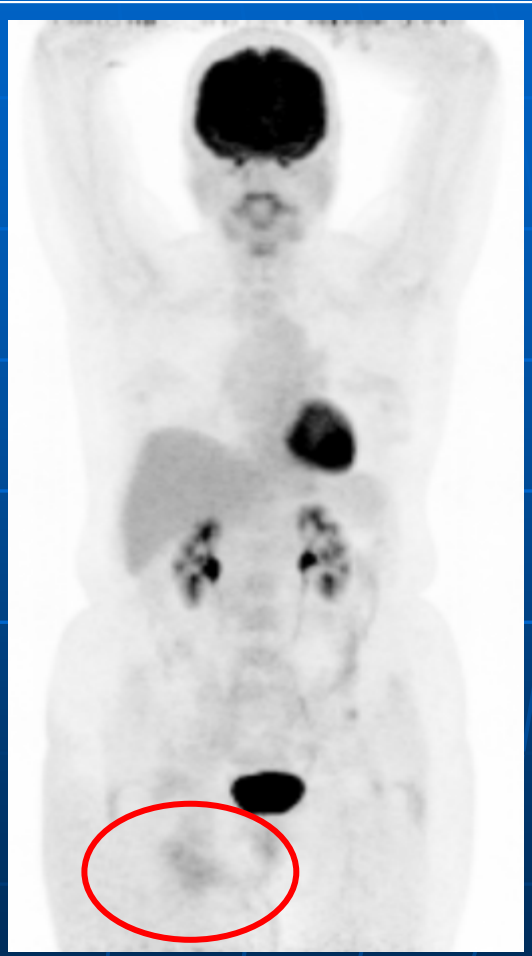

Deauville score 4

Præterapeutisk

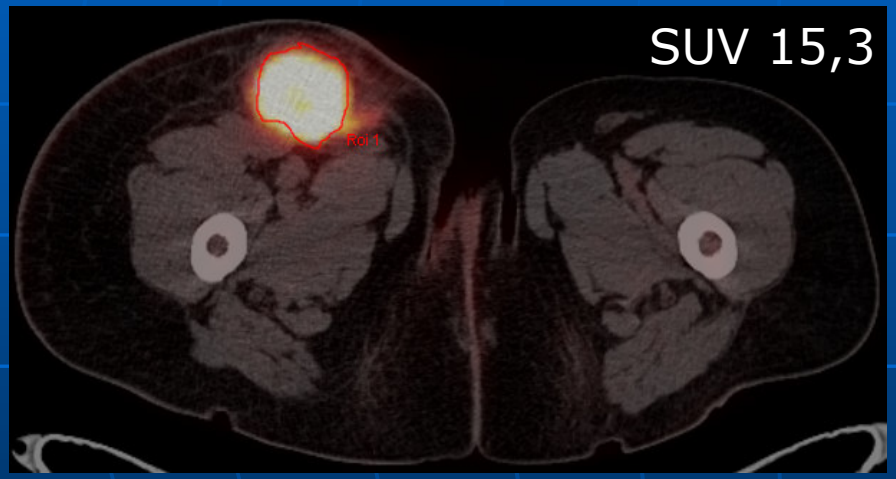

Interim

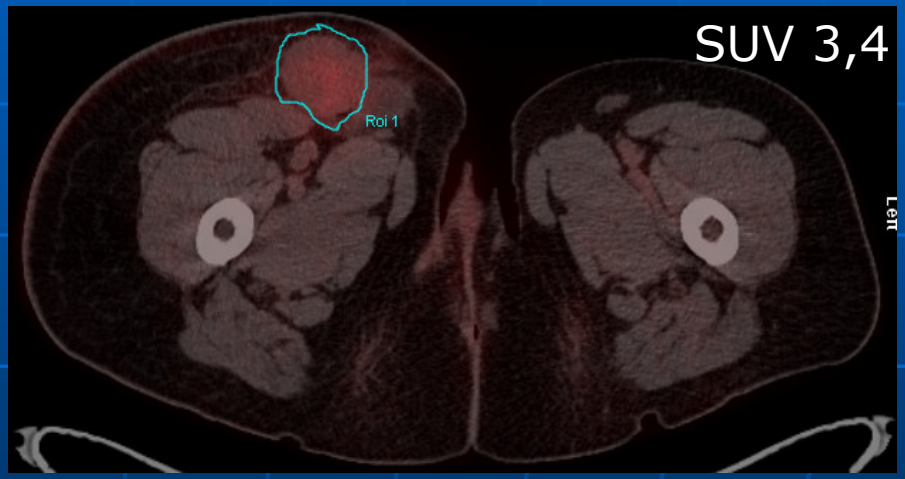

Optagelse ≥ lever (SUV 3,1) ~ DS 4

Cases

Kvinde med DLBCL

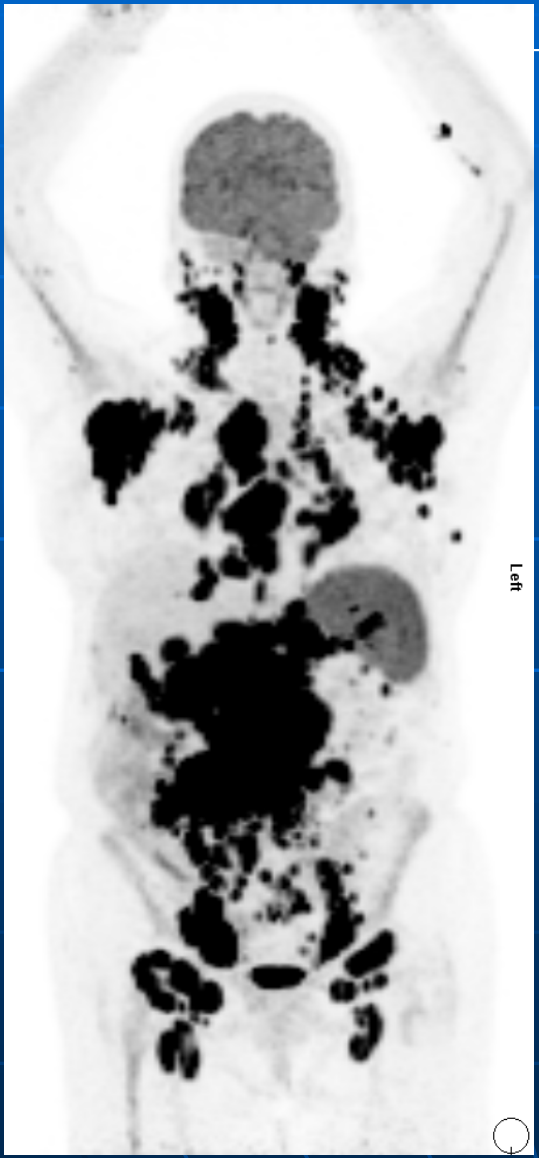

Præterapeutisk staging

1. Samtlige lymfeknudestationer over og under diafragma
2. Involvering af milt
3. Ekstranodale lokalisationer
   a) Knoglemarv
   b) Mamma
   c) Lunge
   d) Subcutant

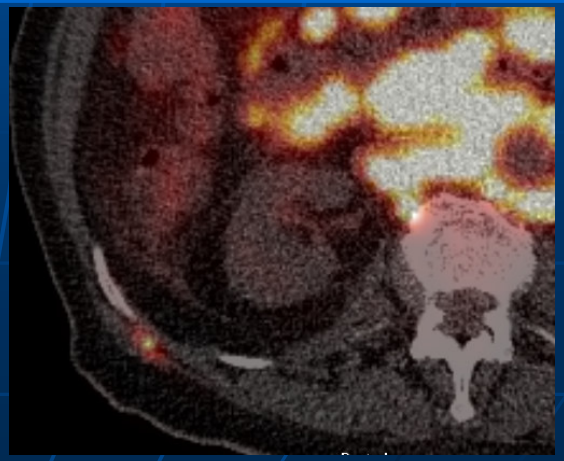

Kvinde med DLBCL

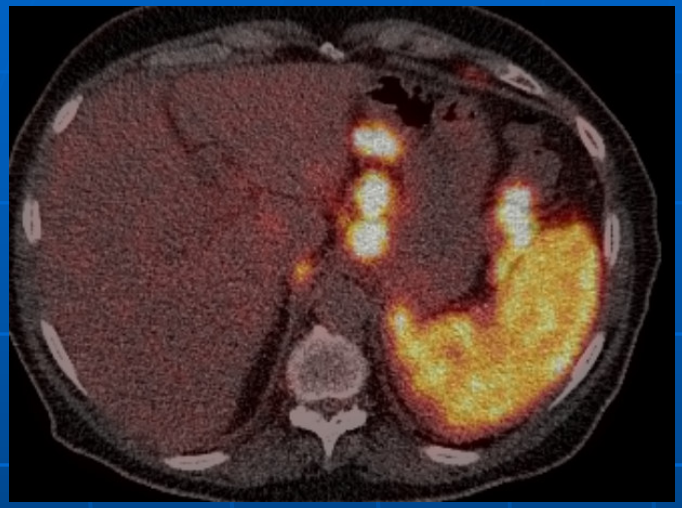

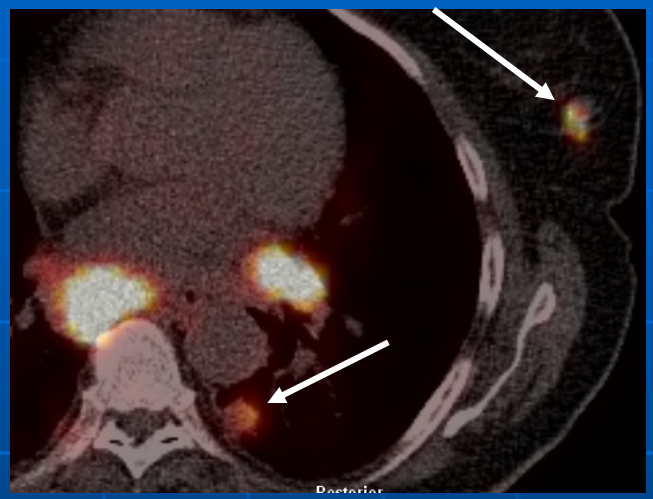

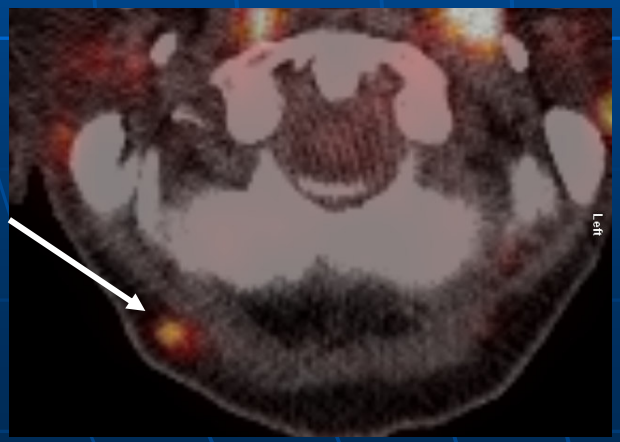

PET viste flere lymfeknuder end CT, knoglemarvs- og miltinvolvering samt fokus i mamma

67-årig mand med CLL
- *transformation OBS*

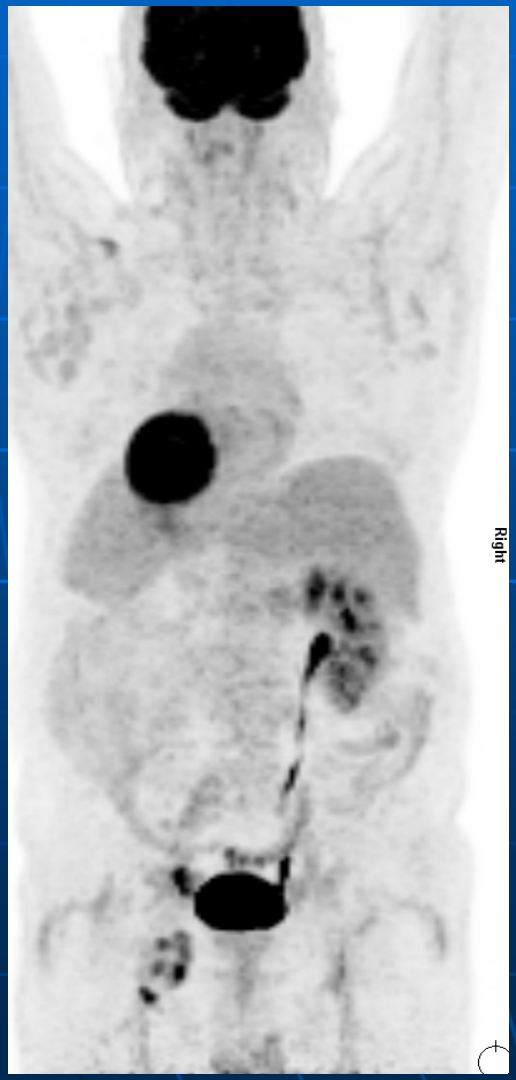

Marts 2011

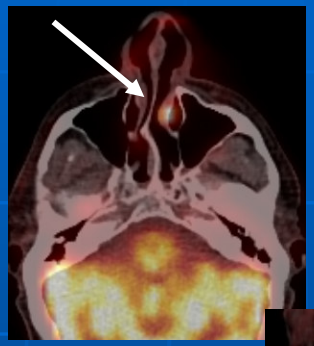

Sekret?

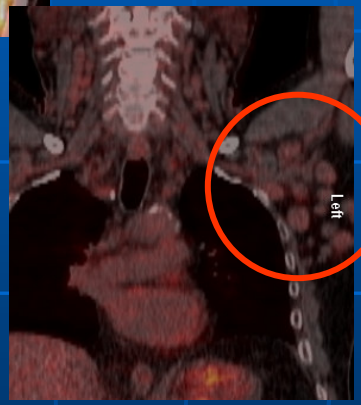

lavmalignt

Transformation?
Granulomatøs sygdom

67-årig mand med CLL
- *transformation OBS*

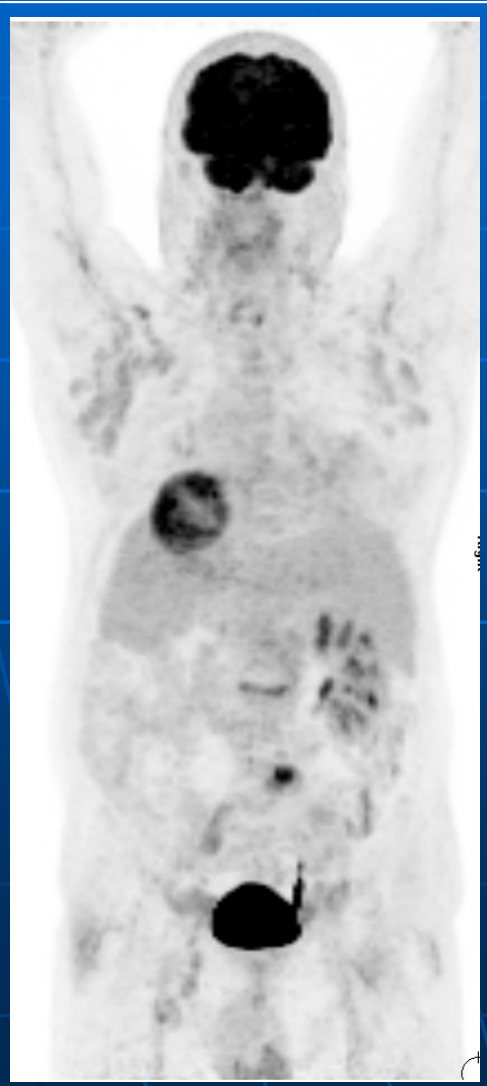

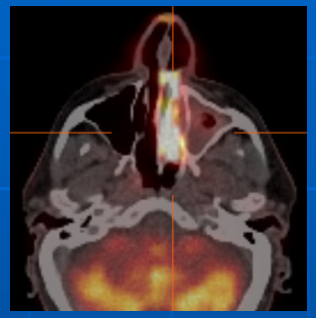

Nov 2011

DLBCL!

Divertikulit

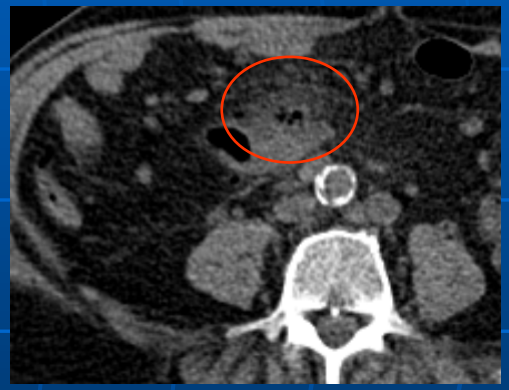

Neurolymfomatose

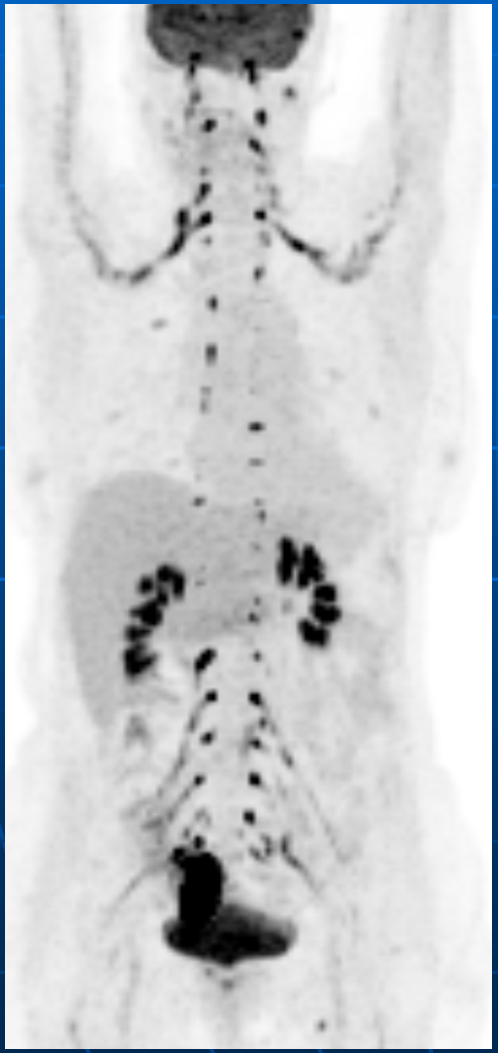

DLBCL med CNS involvering og rygsmerter

Forandringerne sås ikke på CT